Cullote stenting of bifurcation lesion in Y-shaped saphenous vein graft

Tianjin Chest Hospital Lu Cao

Clinical History

- **80 years old, male.**
- **Chief complaint:** intermittent chest depression for sixteen years, aggravated for one month.
- **Risk factors:** Hypertension, Diabetes Mellitus .
- **History of present illness:** He had bypass surgery 8 years prior to admission:Y-shaped vein graft - LAD and DIG, and vein graft -PDA. After that ,the patient insisted on taking medicine. However, he suffered recurrent chest depression on mild exertion from one month ago, which could be relieved by sublingual nitroglycerin. So he was admitted to our hospital for further therapy.

Physical Examination

- BP: 132/68mmHg, clear mentality, supine position, soft neck, no engorgement of jugular vein. Normal breath sound, no dry or moist rales audible. Enlarged heart dullness area , HR: 70bpm, regular, no murmur. Abdomen was soft and flat. Moderate pitting edema in both lower limbs.
- **EKG:**

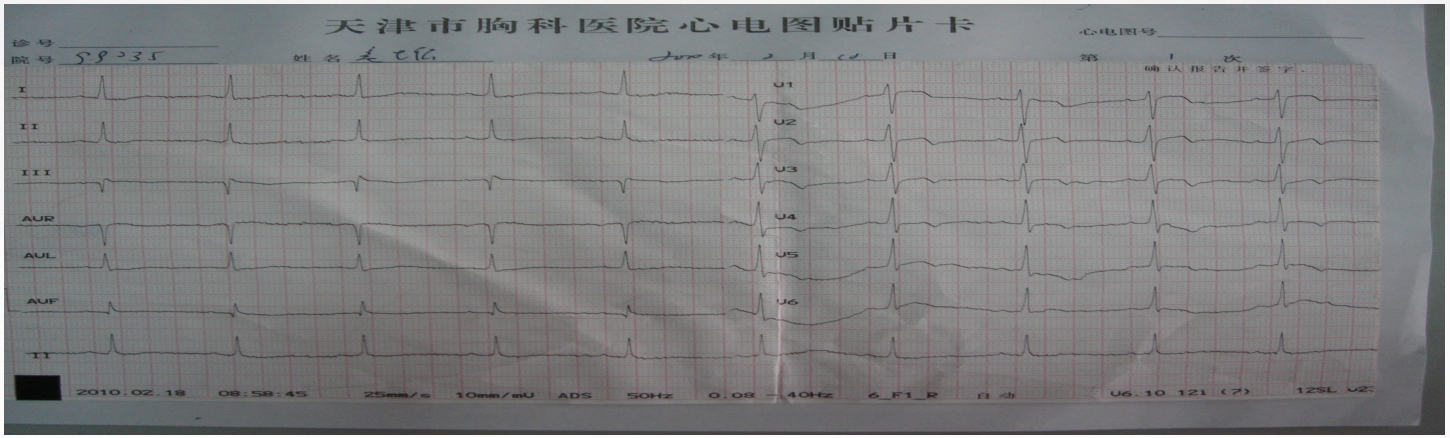

Primary Diagnosis

- 1.Coronary Atherosclerotic Heart Disease

  Unstable Pectoris Angina

  Cardiac Enlargement

  Post CABG

  Heart Function: Grade III (NYHA)
- 2.Type 2 Diabetes Mellitus
- 3.Primary Hypertension

Laboratory tests

- cTnI 0.05ng/ml， CK 110U/L， CK-MB11U/L， TC 4.05mmol/L， TG 1.84mmol/L， HDL-c 1.20mmol/L， LDL-c 2.1mmol/L， NT-proBNP 153.0pg/ml， BUN 5.65mmol/L， Cr 122.1umol/L， Uric Acid 371umol/L， D-dimer 0.1mg/L

- **UCG**： LA： 39mm， LV： 64mm， EF： 56%， pulmonary arterial pressure: 30mmHg， hypokinetic anterior wall, diastolic dysfunction.

Medical Treatment

- Aspirin 0.1 Qd,
- Clopidogrel 75 mg Qd
- Metoprolol 12.5mg Bid
- Imdur,60mg Qd
- Atorvastatin,20mg Qn
- Ramipril 5mg Qd
- Esomeprazole 40mg Qn

CAG

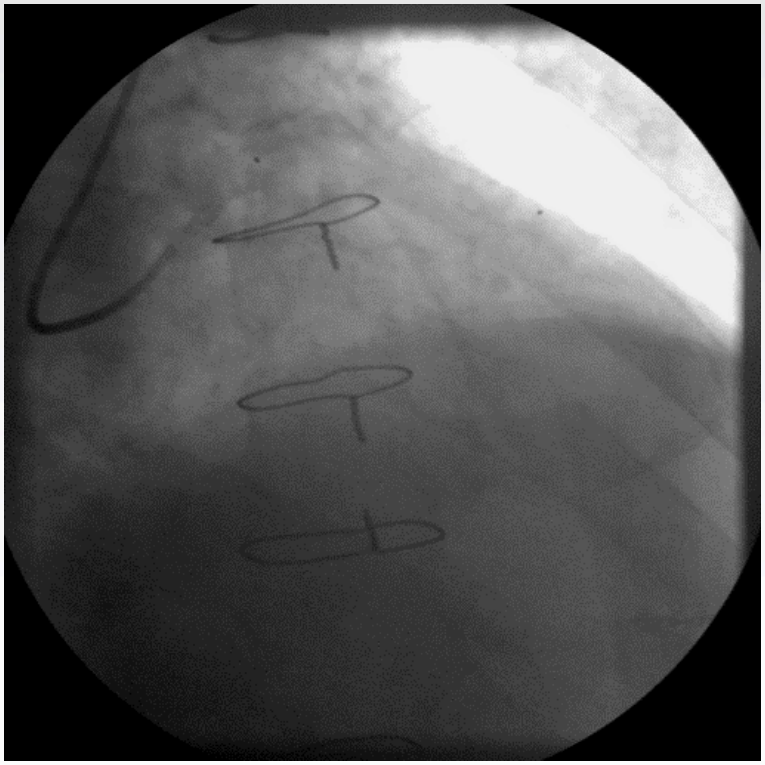

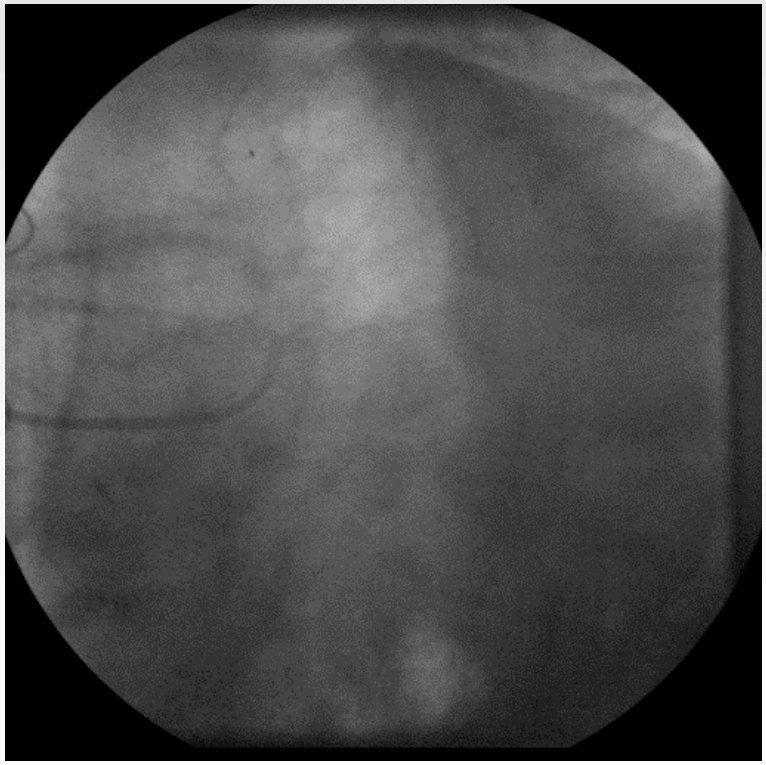

CAG

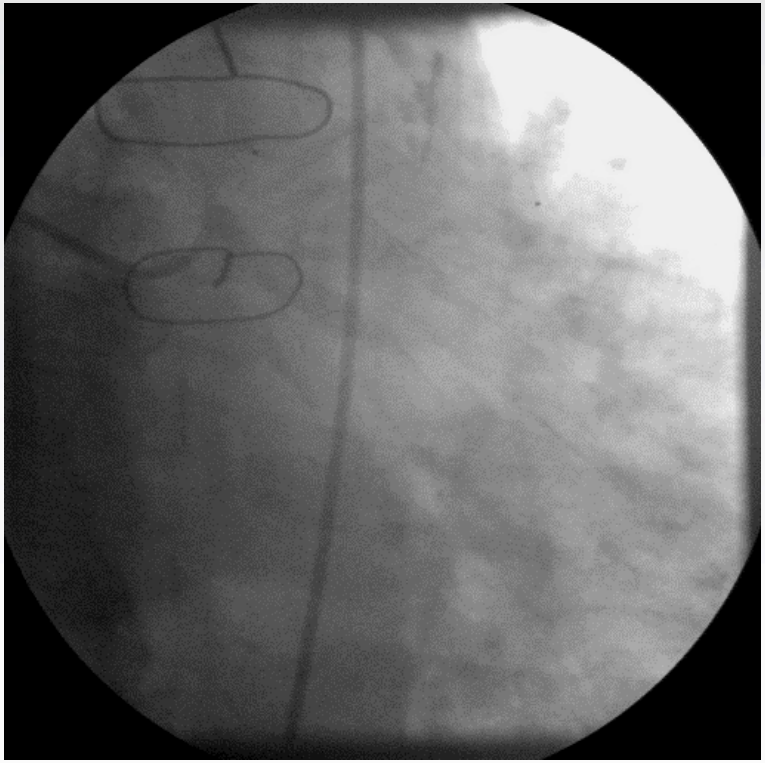

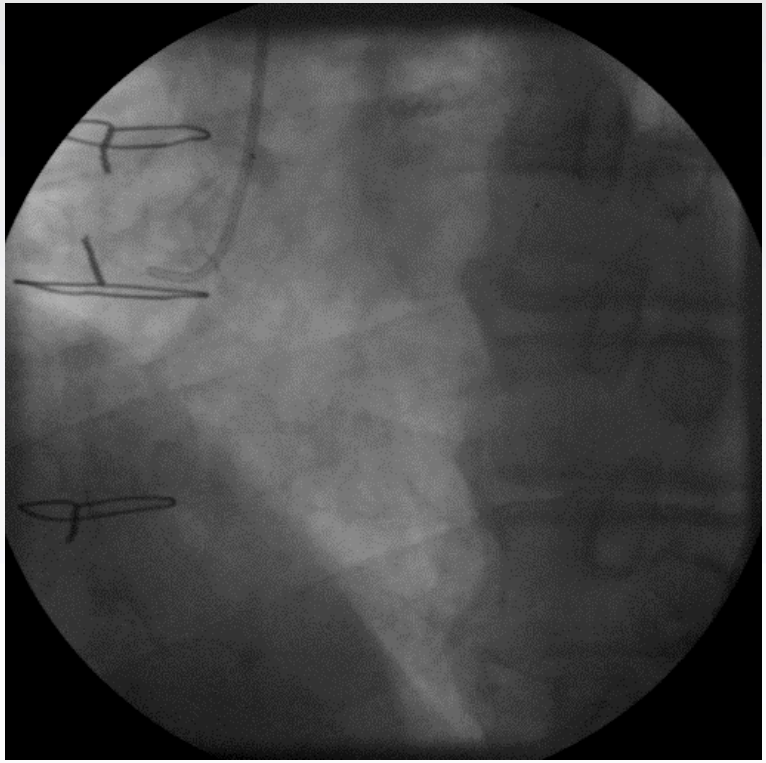

CAG

V-PDA

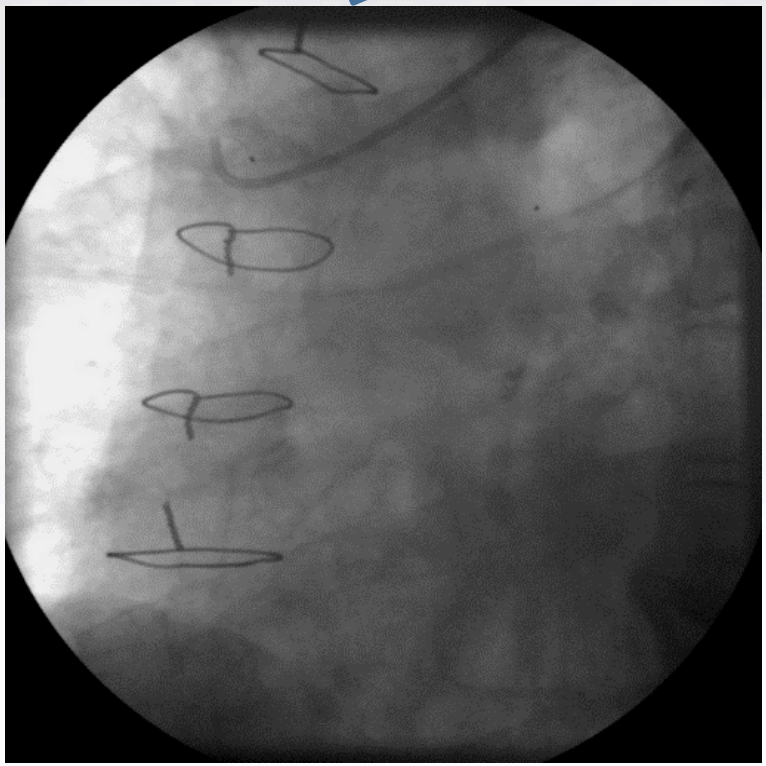

Y-LAD
and Dia

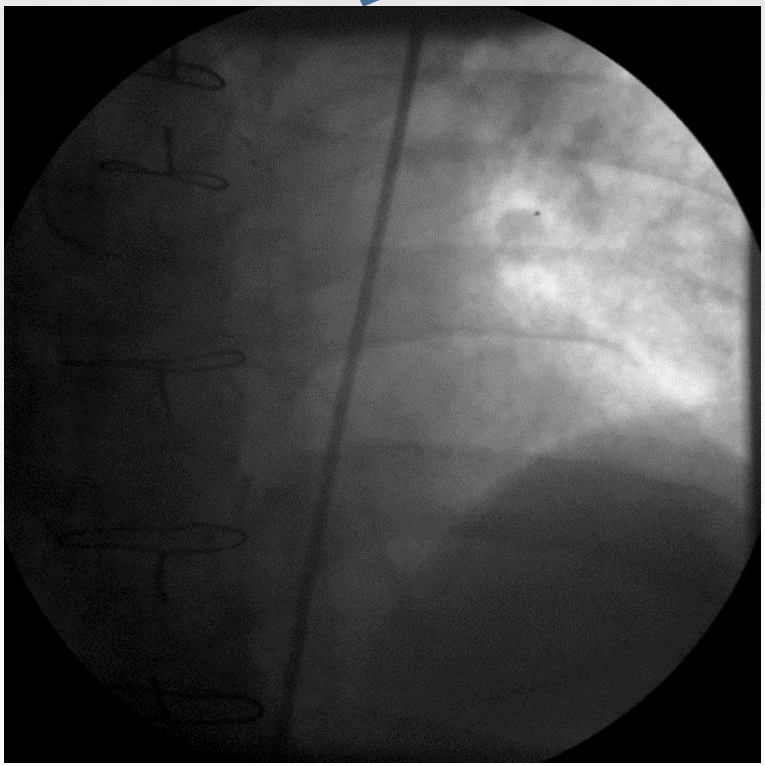

CAG

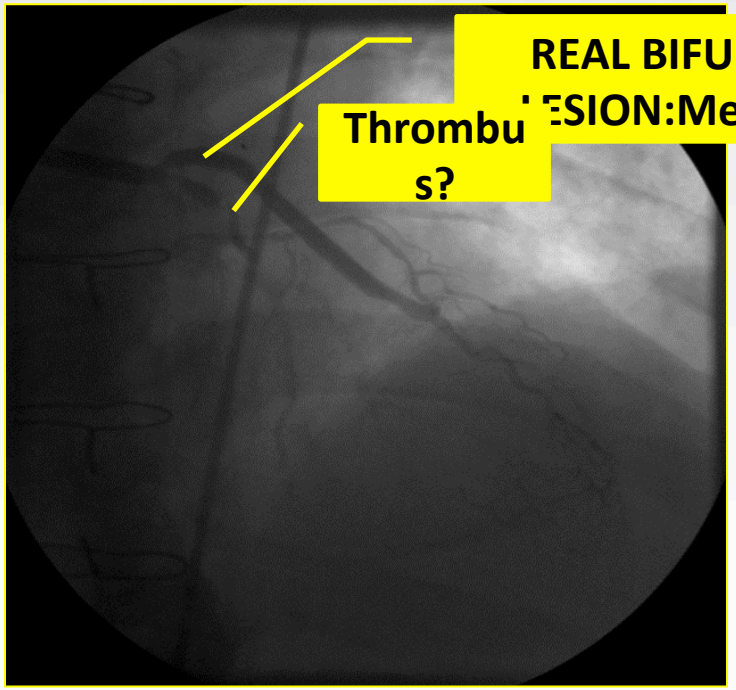

CULPRIT VESSEL

Y-SHAPED VEIN GRAFT

Which is your choice?

PCI OR CABG

Which is your choice?

- CABG: Repeat CABG is being of high risk(two- or four-fold higher than initial CABG)

Better choice

- PCI: native vessel or vein graft?

PCI: native vessel or vein graft?

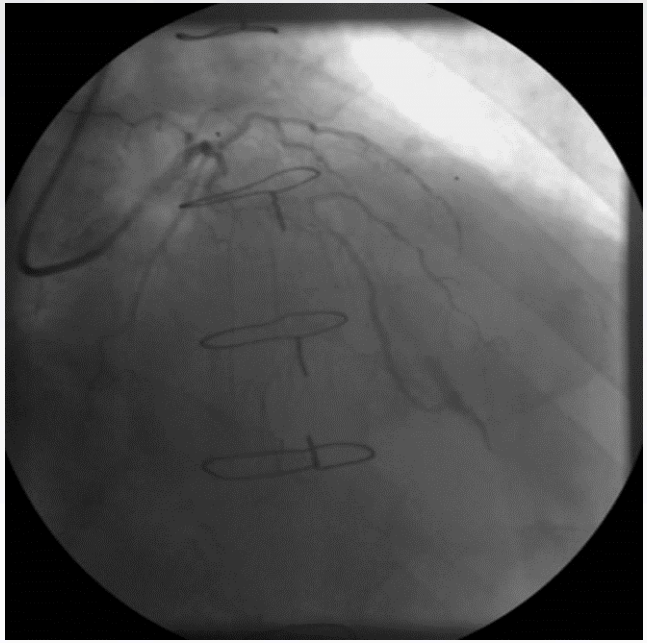

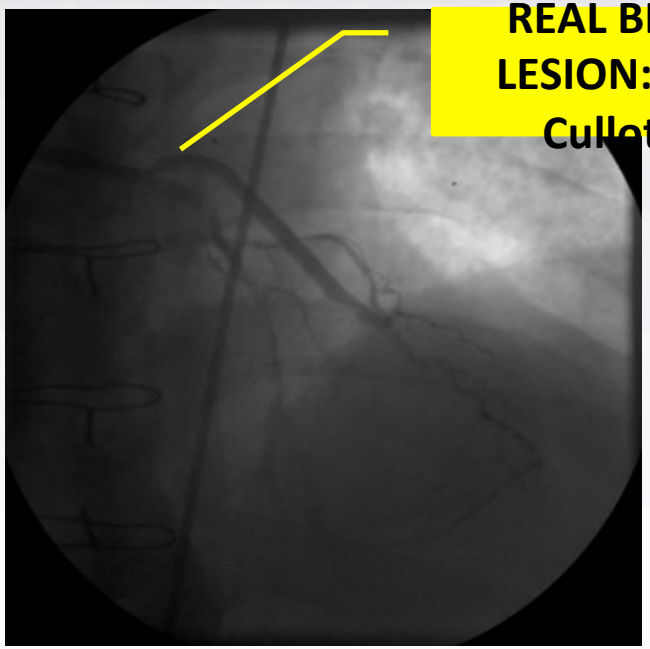

PCI: Aspiration

before

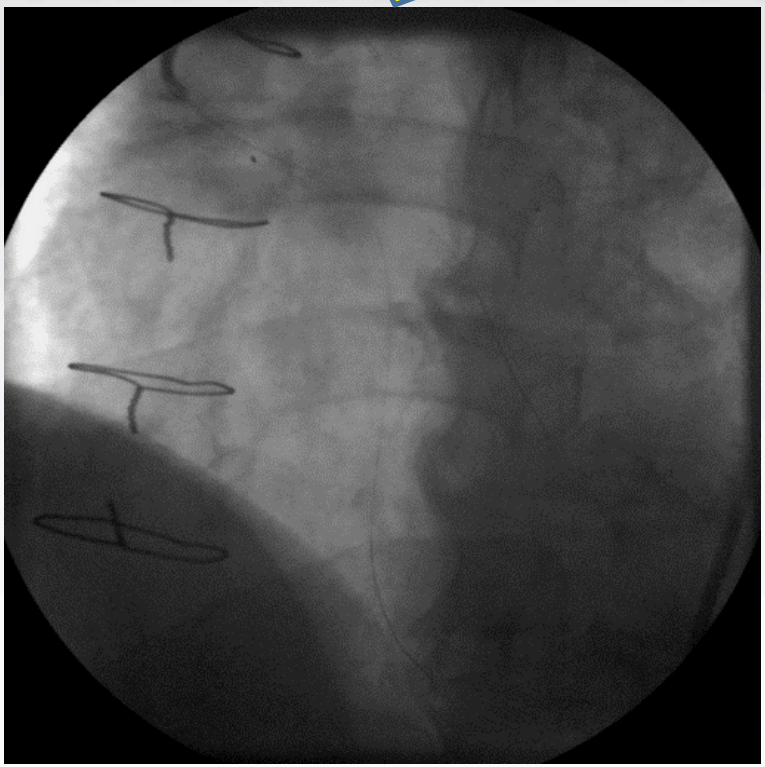

after

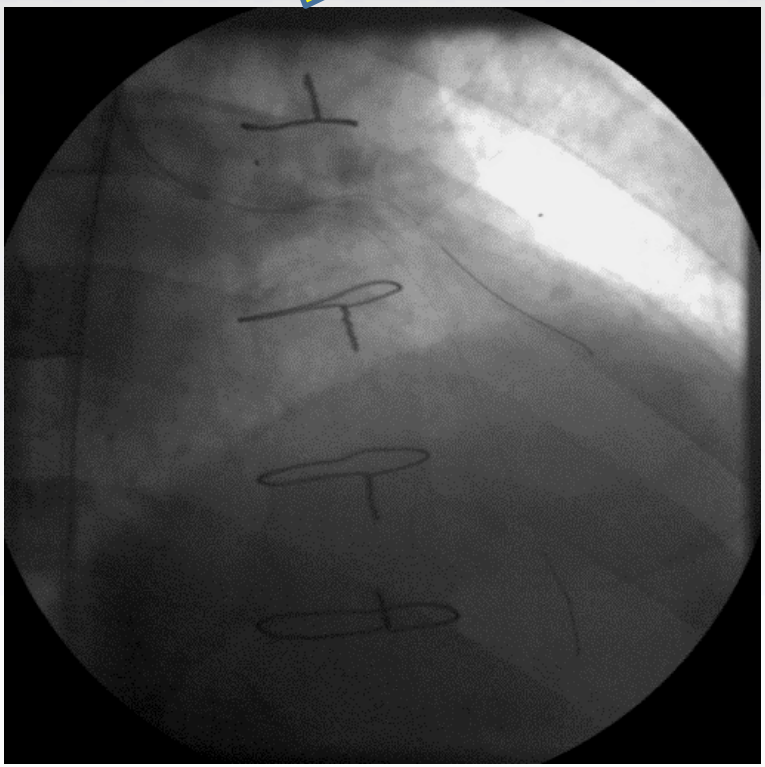

7F $JR_{3.5}$ through femoral artery，BMW*2，PILOT50, Diver CE，Tirofiban

PCI

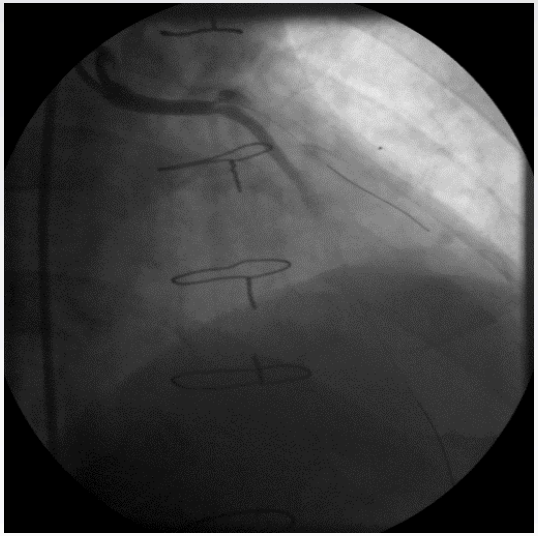

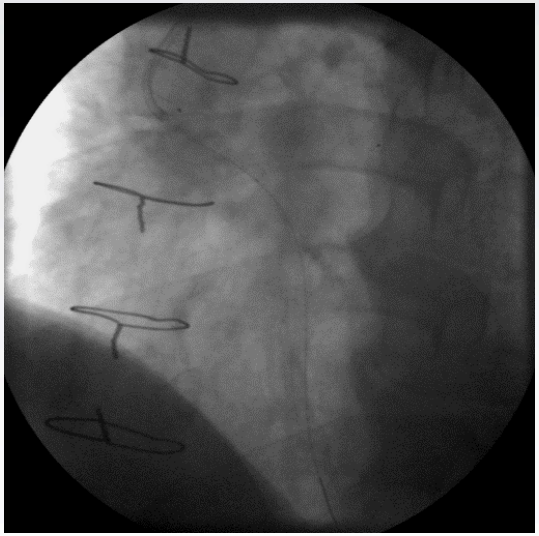

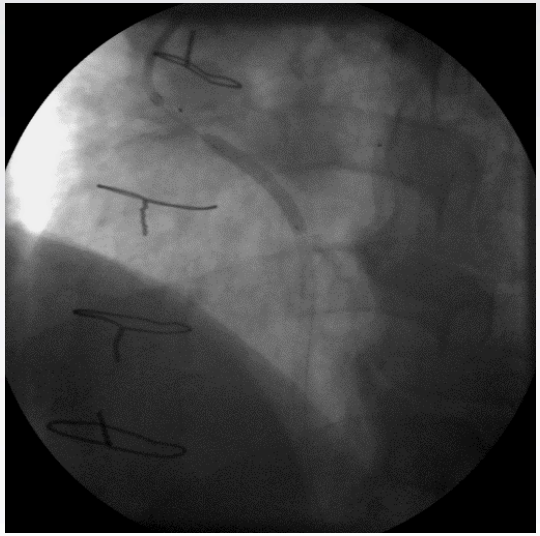

SPRINTER :1.5 ×15mm 、2.5×20mm，FIREBIRD: 4.0 ×33mm、4.0 ×23mm、2*4.0 ×29mm

PCI

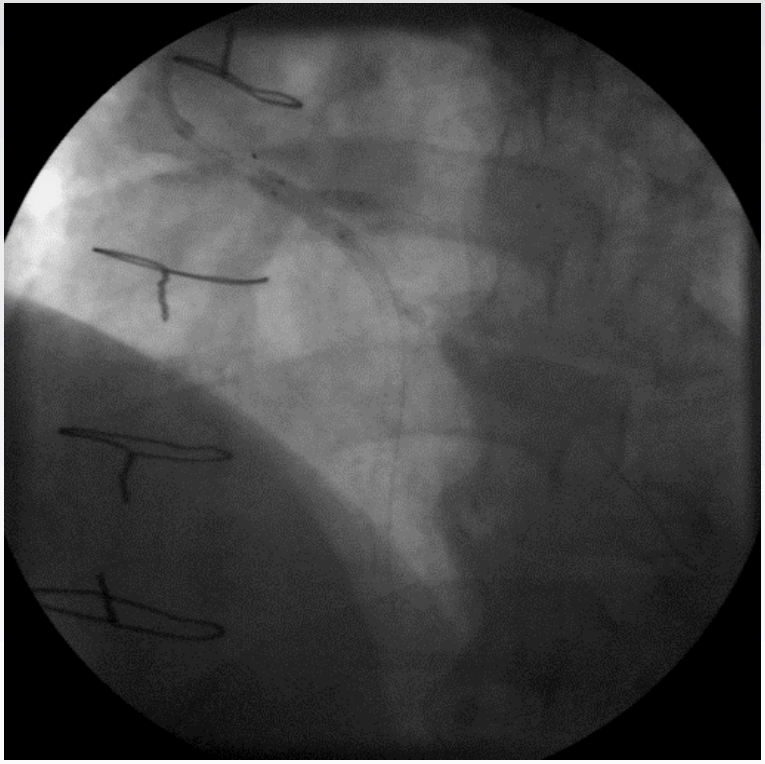

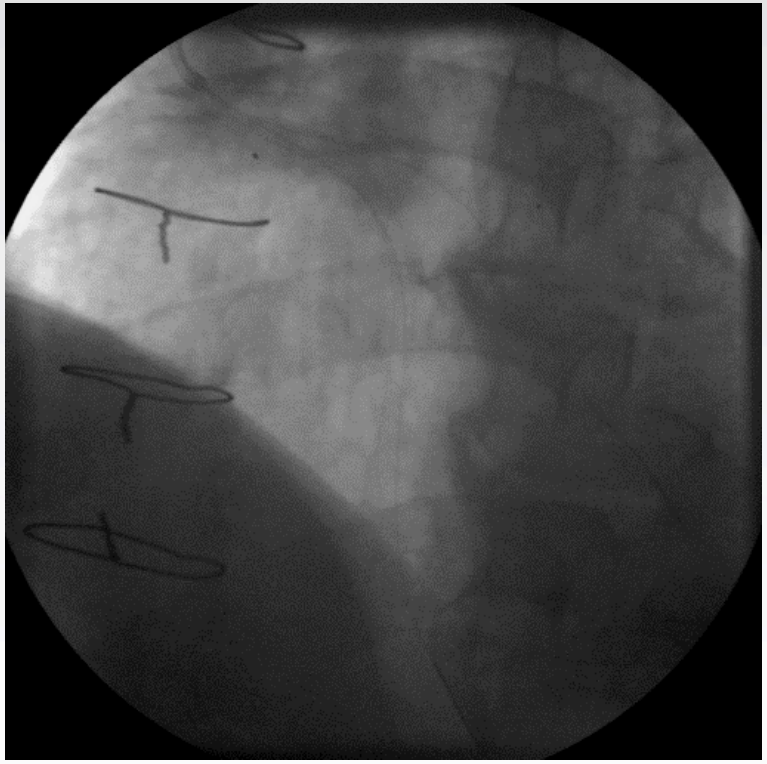

NC MERCURY4.0 ×15mm（8atm）

Follow-up

- No recurrent angina.
- Discharged four days after PCI.
- 6 months later, the patient had not suffered chest pain, dyspnea and palpitation on moderate exertion. NO stroke and bleeding complications happened.

Thank you !