

***Welcome to the 4<sup>th</sup>  
European Bifurcation Club  
26-27 September 2008 - PRAGUE***

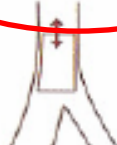
















# CONSENSUS or NOT

*European Bifurcation Club*



***Dr. Goran Stankovic***

# Conventional Stenting Techniques

	<b>M</b> Main prox. first	<b>A</b> Main Across side first	<b>D</b> Distal first	<b>S</b> Side branch first		
1 <sup>st</sup> stent	 PM stenting	 MB stenting across SB	 DM stenting	 SB ostial stenting		
After balloon	 Skirt	 MB stenting + SB balloon	 MB stenting + kissing	 SB minicrush	 SB crush	
2 stents	 Skirt + DM	 Elective T stenting	 V stenting	 Syst. T Stenting	 Minicrush	 Crush
3 stents	 Extended V		 Trouser legs and seat			



# M-Family:

## How to perform with Devax or Extended Y-Stenting

- Case Selection

- Large side branches
- Diffuse disease
- Significant diameter changes between proximal PV and distal PV or SB

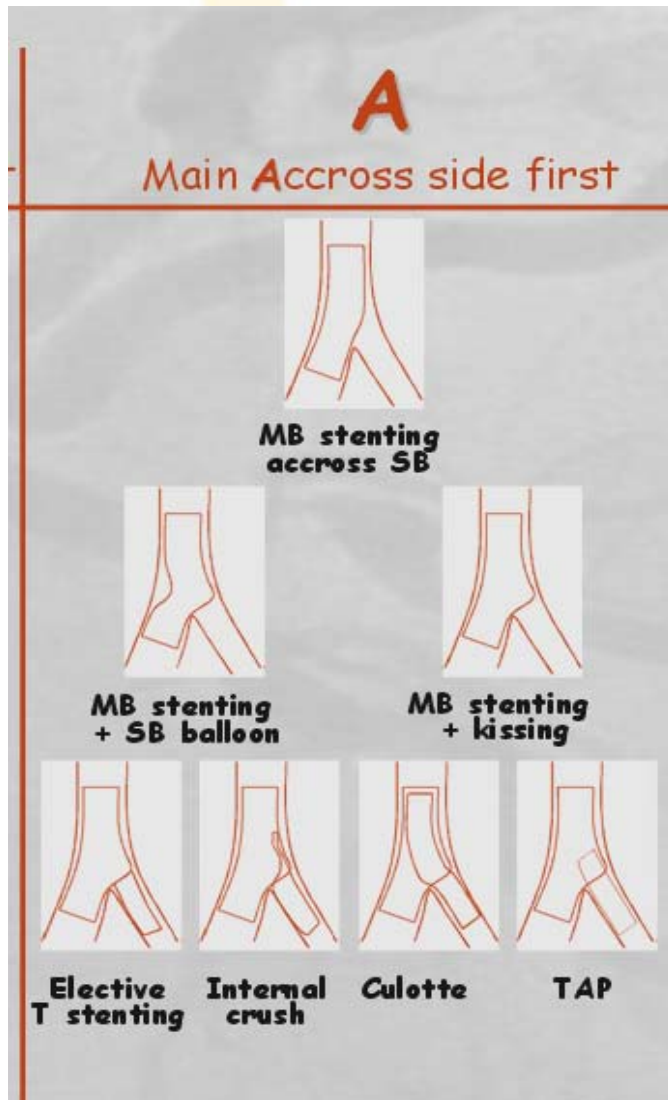
- Advantages:

- Maintains SB access and removes risk of SB occlusion
- Removes risk of proximal dissection
- Maximum treatment flexibility for complex anatomy

- Disadvantages

- Stent number
- Requires high precision placement
- Proximal stent too distal or too proximal to carina

# “A” Family Techniques




“...beginning by stenting the main vessel across the side branch, and then allowing techniques like provisional T, elective T stenting, classical Culotte ...It is also the strategy for the most frequently used dedicated stents (Petal, Minvasys, Frontier, Invatec...)”

Y Louvard

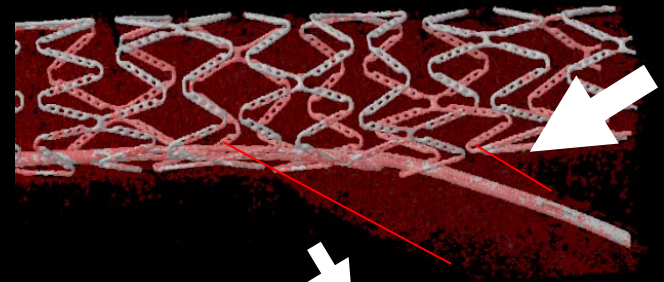


# Stenting MV across the SB. Distal wire cross creates better SB scaffolding than prox



Proximal cross




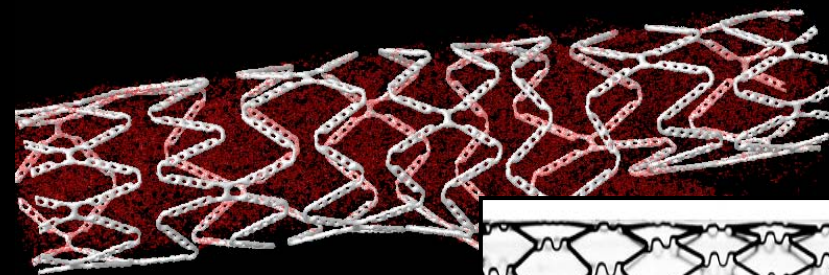

Distal cross



Single balloon SE dilatation



Kissing balloon post-dilatation



# Crush-Stenting. Proximal wire cross creates better SB scaffolding than distal crossing

## Consensus

- *In provisional SB stenting cross through the distal strut (“Carina cell”)*
- *In crush stenting proximal wire cross creates better SB scaffolding than distal crossing*



# How to do a Provisional T Stenting

**Should we use a jailed wire?**

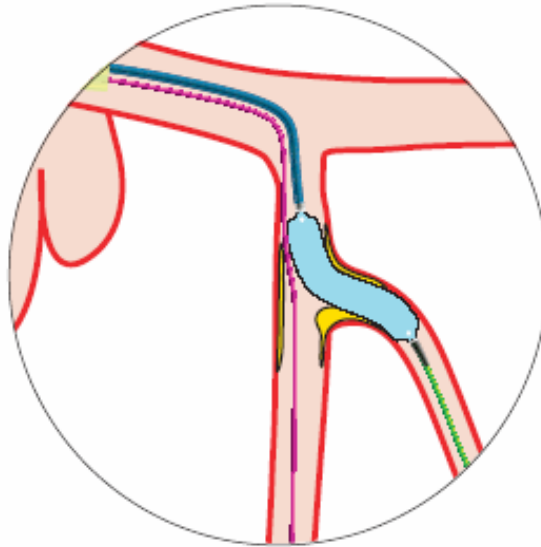
- **Yes**

1. Modifies favorably the angle between both br.
2. Keeps the side branch open
3. Is a good marker of SB

# How to do a Provisional T Stenting

## Should we predilate the SB?

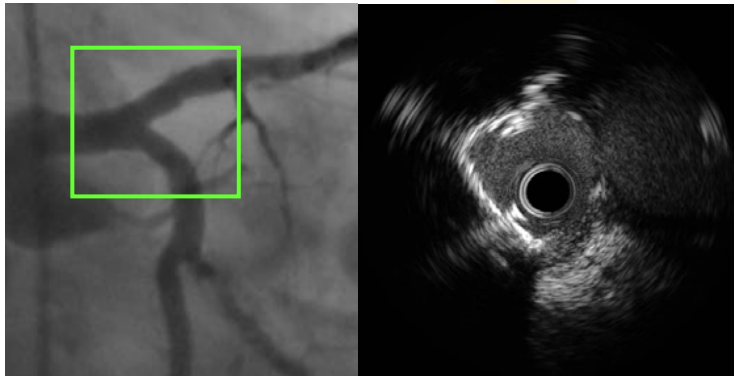
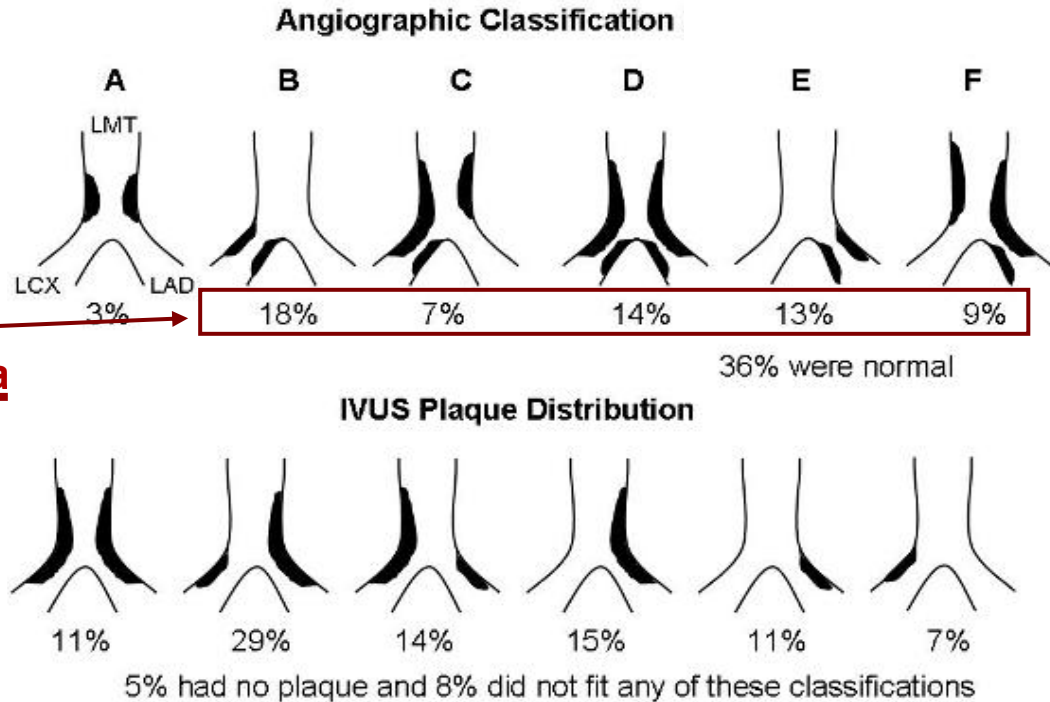
- **No**
- *Yes, if calcified lesion*
- *Yes, if long lesion (on SB)*





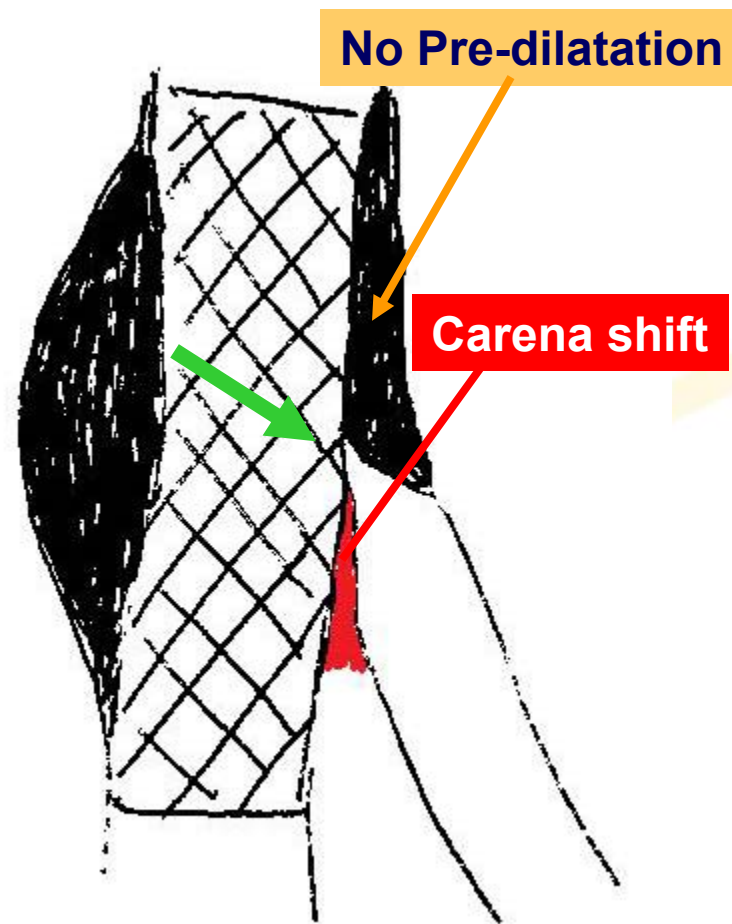
# A critical intravascular ultrasound appraisal of the angiographic classification of bifurcation lesions: *Where is the plaque really located ?*

- **Methods:** 73 angiograms of distal left main (LM), left anterior descending (LAD) and left circumflex (LCX) lesions with pre-intervention IVUS of both the LAD and LCX as well the LM.
- **Results:** **Angiography** suggested that the carina was involved in **61%**. However, **IVUS showed that the carina was spared in all 73 pts (Figure).**
- **Conclusions** IVUS studies show that the carina is always spared and that the disease is rarely focal.



# The case of true bifurcation (1,1,1)

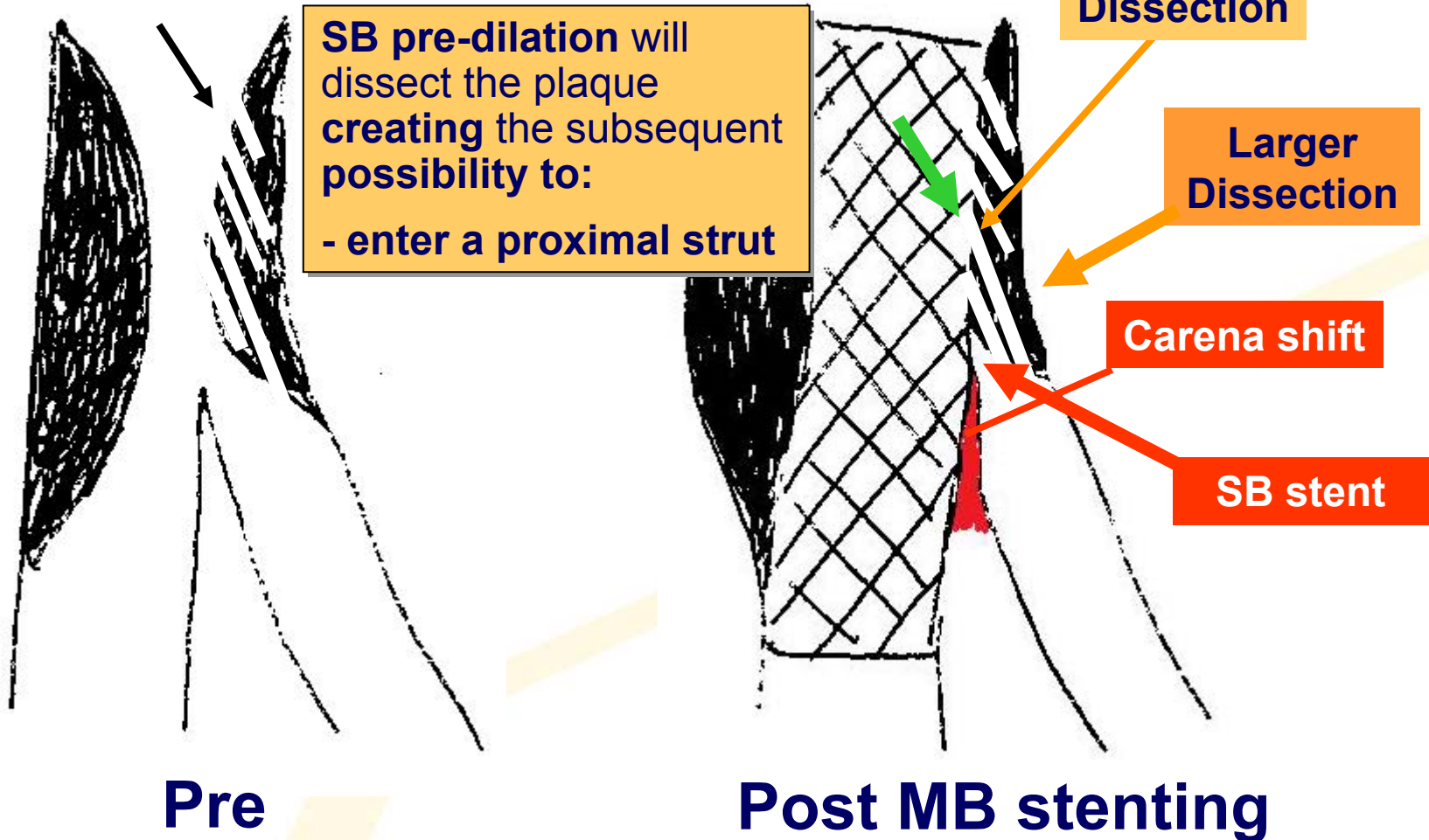
- We should **avoid Side Branch pre-dilatation** and **take advantage of the carena shift**
- the guidewire (GW) will cross the stent strut **exactly at the carena**



**Post MB stenting**

# The case of true bifurcation (1,1,1)

## Pre-dilatation->Dissection

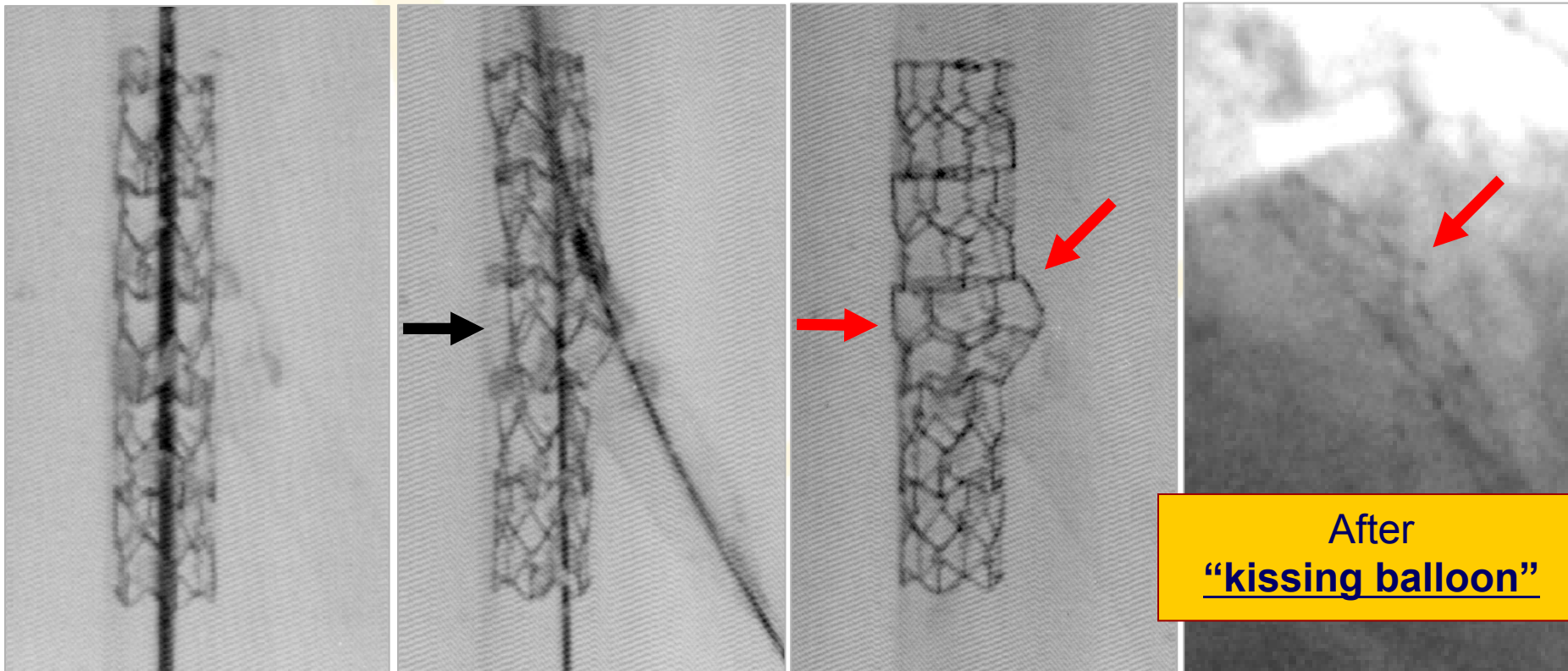


## Consensus

- ***“Carina shift” not “plaque shift”***
- ***No need for routine SB predilatation unless lesion in the SB long and/or severely calcified***

# How to do a Provisional T Stenting

- The role of kissing balloon:
- 1) Corrects stent deformation
  - 2) Scaffolds SB ostium





## CACTUS trial

Coronary Bifurcation Application of the Crush Technique Using Sirolimus-Eluting stents

### *Final kissing balloon inflation*

	<b>YES</b>	<b>NO</b>	<b>P value</b>
<b>Myocardial infarctions</b>	7.5% (24/319)	29.0% (9/31)	<0.0001
<b>Stent thrombosis</b>	0.9% (3/319)	6.5% (2/31)	0.06



## CACTUS trial

Coronary Bifurcation Application of the Crush Technique Using Sirolimus-Eluting stents

### *Final kissing balloon inflation*

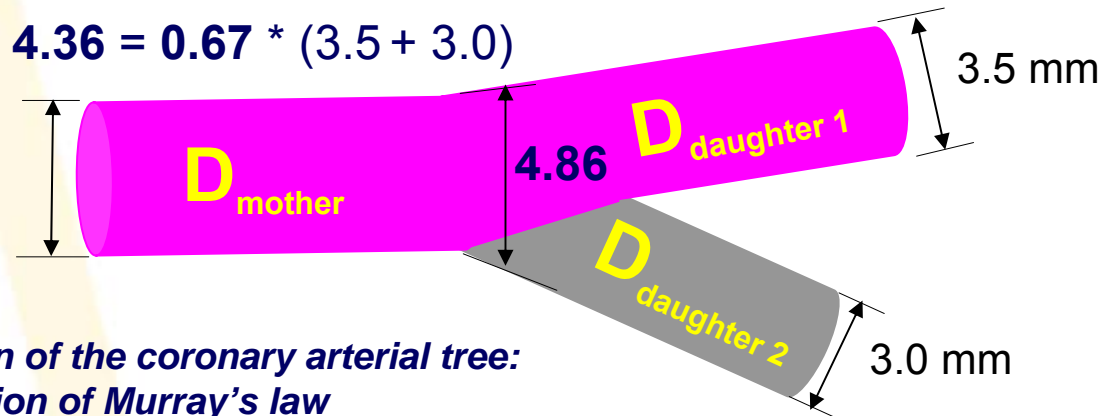
	<b>YES</b>	<b>NO</b>	<b>P value</b>
<b>MB restenosis</b>	4.7%	16%	0.03
<b>SB restenosis</b>	11.9%	36%	<0.001

## **Consensus?**

***Final kissing balloon inflation  
necessary in complex stenting and  
may also improve angiographic  
and clinical outcome in provisional  
stenting;***

***we need data from randomized trial  
(Nordic-KISS)***

# Maximum (Declared) Stent Diameter



*On the design of the coronary arterial tree:  
a generalization of Murray's law*

$$D_{\text{mother}} = 0.67 * (D_{\text{daughter 1}} + D_{\text{daughter 2}})$$

*Yifang Zhou et al. Phys. Med. Biol. 44 (1999) 2929–2945.*

**Cypher 3.5**

Max diameter **4.75 mm**

**TAXUS 3.5**

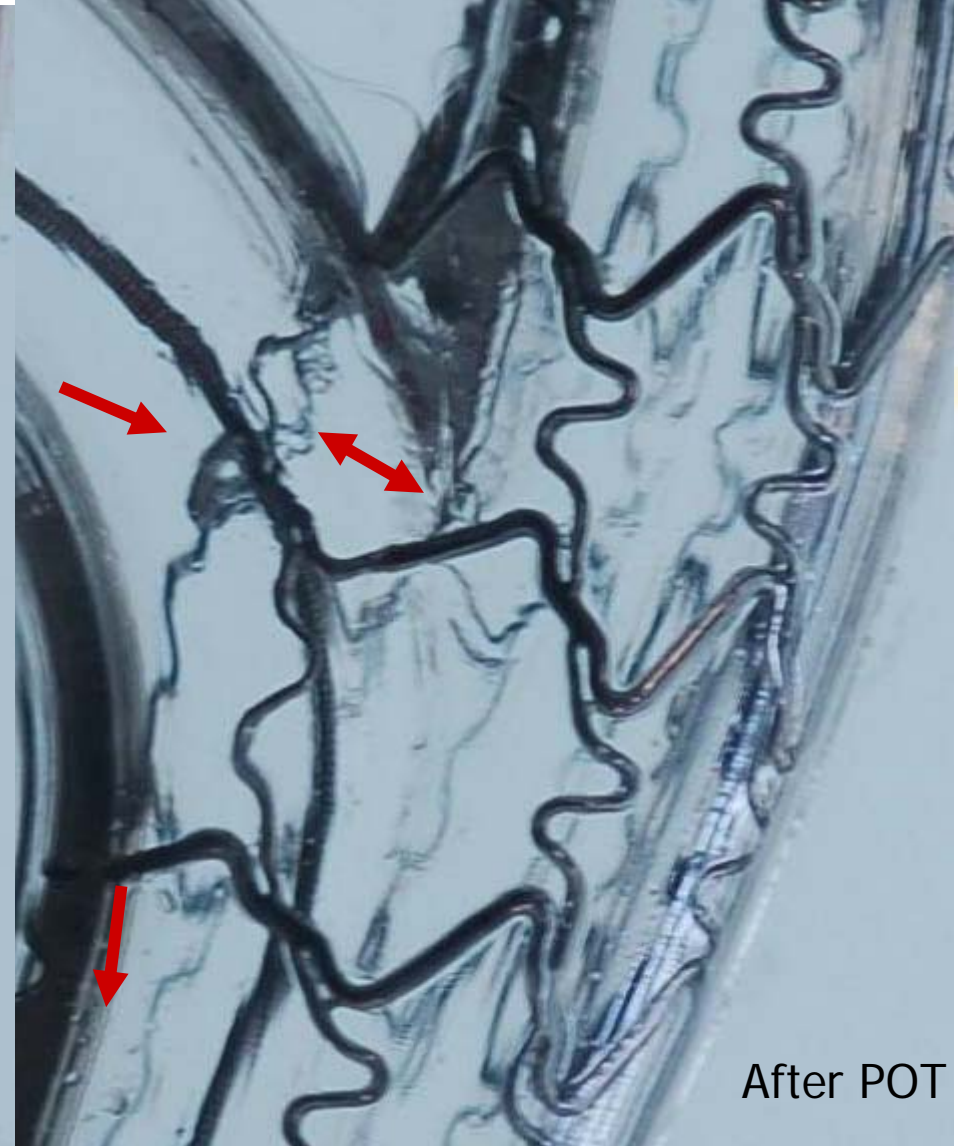
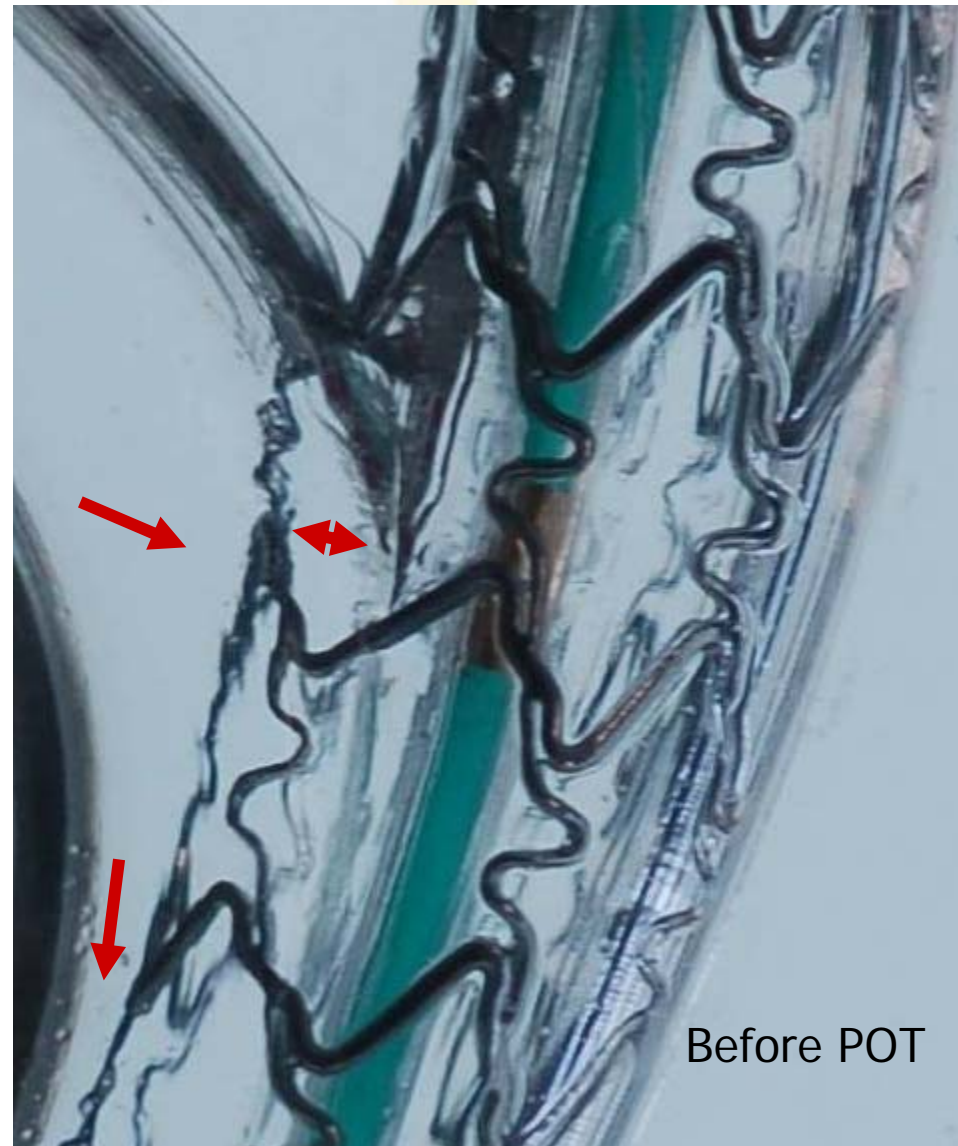Max diameter 4.25 mm

**TAXUS 4.0**

Max diameter **5.75 mm**



# Cypher Select 3.5 x 23mm



# Combining information of the ostium and stent cell size

Stent	Company	Cell circumference [mm]	Equivalent diameter [mm]
Cypher	Cordis	9.5	3.0
Endeavor	Medtronic	19.8	6.3
PRO-Kinetic	Biotronik	10.8	3.4
Promus*	Boston Scientific	12.6	4.0
Taxus Liberté	Boston Scientific	12.6	4.0


























- Stent cell circumference should preferably be as large as the ostium circumference
- Applying this criterion does not guarantee that all struts will be in contact with the tissue!
- But, it helps to select stents which have at least the potential to be sufficiently enlarged



## **Consensus**

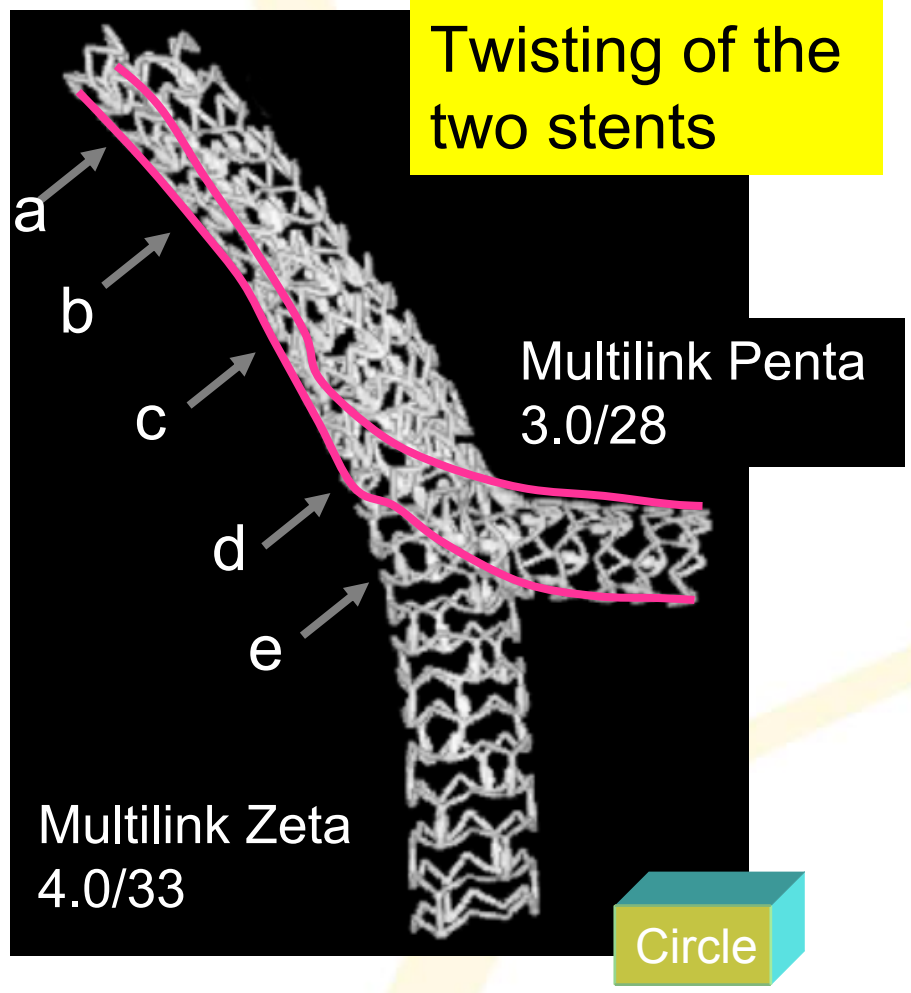
***Stent choice is important***

# Conventional Stenting Techniques

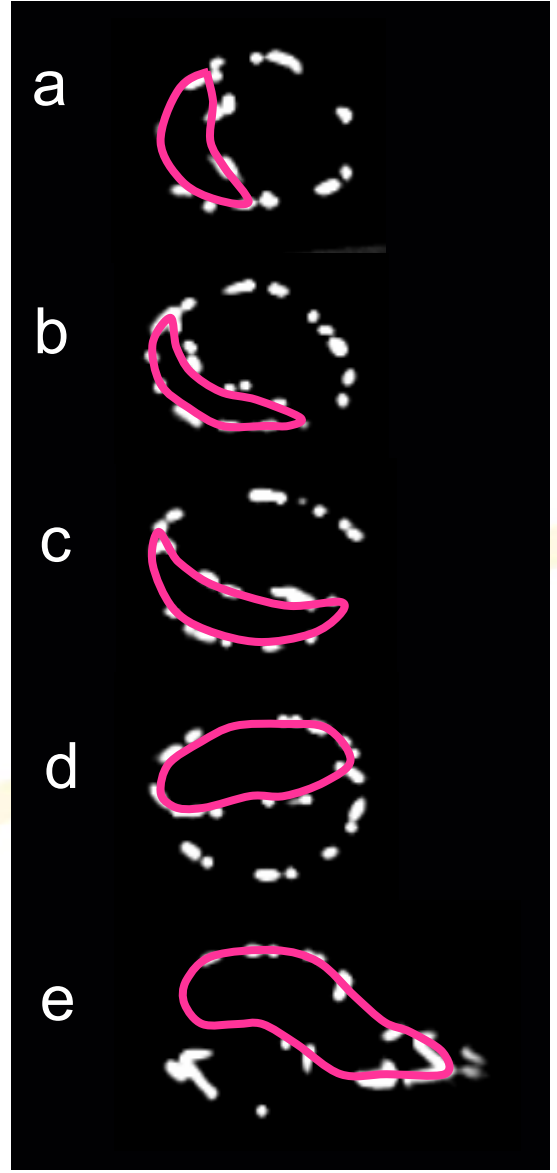
	<b>M</b> Main prox. first	<b>A</b> Main Across side first	<b>D</b> Distal first	<b>S</b> Side branch first							
1 <sup>st</sup> stent	 PM stenting	 MB stenting across SB	 DM stenting	 Provisional SKS	 SB ostial stenting						
After balloon	 Skirt	 MB stenting + SB balloon	 MB stenting + kissing		 SB minicrush	 SB crush					
2 stents	 Skirt + DM	 Skirt + SB	 Elective T stenting	 Internal crush	 Culotte	 TAP	 V stenting	 SKS	 Syst. T Stenting	 Minicrush	 Crush
3 stents	 Extended V		 Trouser legs and seat								



# Simultaneous kissing stent (SKS) and V-stent Long kissing stenting in LMCA



Cross sectional view





# Simultaneous kissing stent (SKS) and V-stent

## Indication

- ◆ (1-1-1) for SKS  
(0-1-1) for V-stent
- ◆ Large proximal MV

## Merits

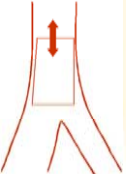


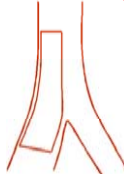
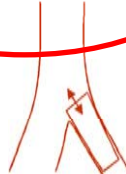
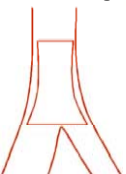

















- Non-complex procedure
- Speedy
- No loss of the SB
- Less hemodynamic instability
- **Good for emergency situations**
- **case without wide angled bifurcation**

## Drawbacks

- Large GC (8Fr)
- Metallic carina
  - Flow disturbance
  - Thrombogenesis
- Over dilatation in proximal MV
- Gap formation beneath the crossing point of the two stents
- Difficulty in additional treatment
  - GW recross
  - Proximal stenting
- Longitudinal stent overlapping in high-angle bifurcation.



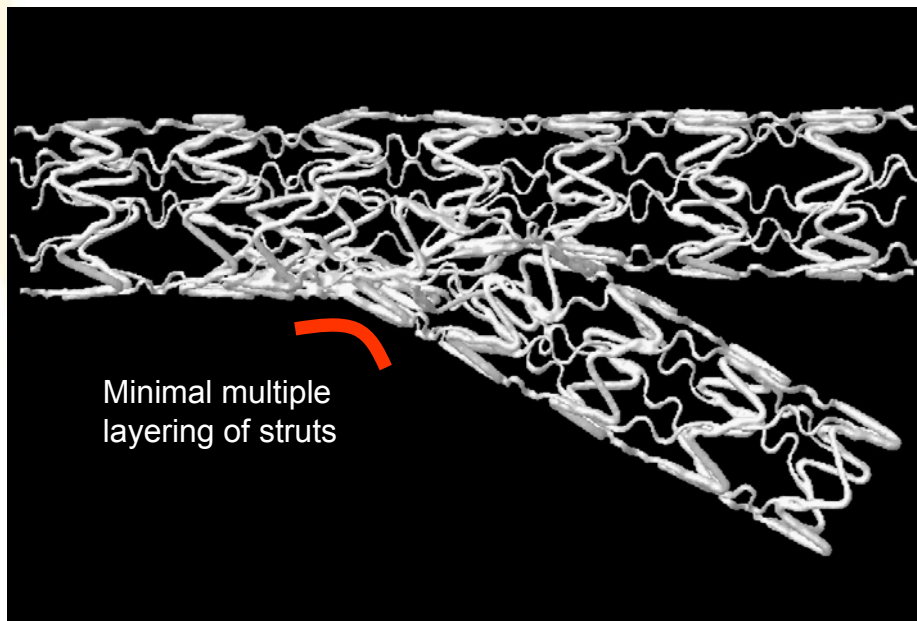
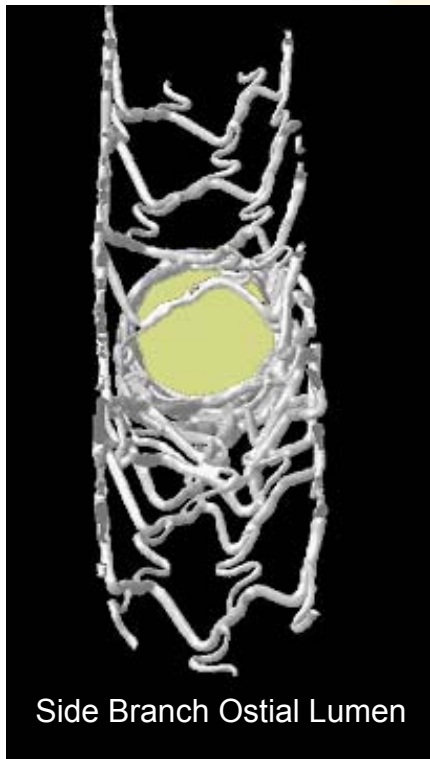
# Conventional Stenting Techniques

Intention	<b>M</b>	<b>A</b>	<b>D</b>	<b>S</b>
Final	Main prox. first	Main Across side first	Distal first	Side branch first
1 <sup>st</sup> stent	 PM stenting	 MB stenting across SB	  DM stenting    Provisional SKS	 SB ostial stenting
After balloon	 Skirt	  MB stenting + SB balloon    MB stenting + kissing		  SB minicrush    SB crush
2 stents	  Skirt + DM    Skirt + SB	    Elective T stenting    Internal crush    Culotte    TAP	  V stenting    SKS	   Syst. T Stenting    Minicrush    Crush
3 stents	 Extended V		 Trouser legs and seat	

# Mini-Crush Technique Bench Work

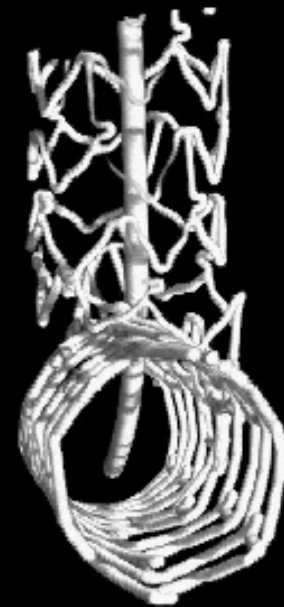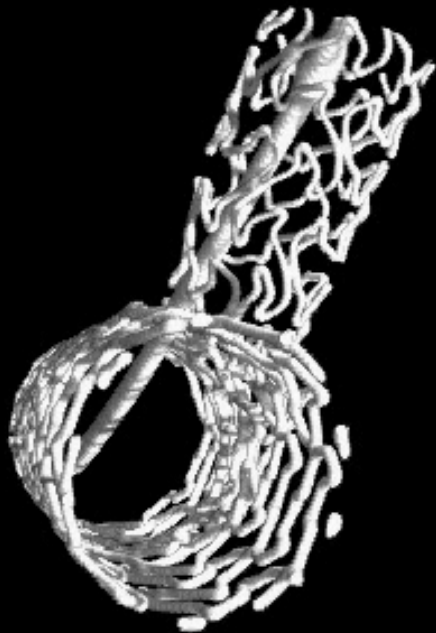
Courtesy of J. Ormiston (Mercy Angiography, New Zealand)

## 30° Degree Model



	n	Side-Branch Ostial % Area Stenosis	p Value
		Mean (95% CI)	
Deployment strategy			
Classical crush	32	47 (39–53)	0.002
Mini-crush	26	36 (31–40)	
Post-dilation strategy			
1-step kissing	26	53 (46–59)	<0.0001
2-step kissing	32	33 (28–37)	
Stent cell size*			
<3.5 × 3.5 mm	18	52 (44–60)	<0.0001
>3.5 × 3.5 mm	40	37 (32–42)	

# Crush or Minicrush ?





# DK-Crush: Clinical Outcomes: 8-month f-up

	Classical Overall	Classical - FKBI	Classical + FKBI	DK Crush	P Class vs. DK
# Lesions	156	39	117	155	
MACE	24.4	35.9	19.7	11.4	0.02
Cardiac death	1.7	2.5	2.5	0.6	0.5
Q-wave MI	3.5	5.1	0.9	1.2	0.7
Non-Q-wave MI	11.1	10.2	8.1	9.1	0.9
TLR	18.9	22.6	17.8	9.0	0.03
TVR	21.9	26.5	20.0	10.3	0.03
Stent Thrombosis	3.2	5.1	1.7	1.3	1.0

**Chen et al. – DKCRUSH-1 Bifurcation Study: classical vs. DK crush with DES**

P<0.001 vs. Classical+FKBI or DK Crush

P=0.05 vs. Classical+FKBI



## **Consensus**

***For S family we should select  
mini-crush and/or DK-crush***



# Distal BA, enddiastolic values (n=266)

- Systolic-diastolic motion affects the bifurcation angulation
- PCI treatment affects the distal bifurcation angle

## Pre PCI

Mean=95,6  
SD= 23,9  
Med= 96,0  
Max= 165  
Min= 44

## Post PCI

Mean=91,0  
SD= 22,2  
Med= 91,0  
Max= 146  
Min= 39

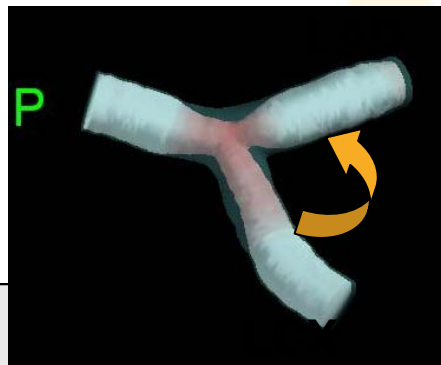**p<0.001**

(deg)

(deg)

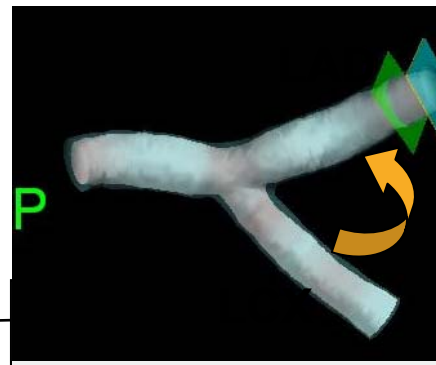


# Distal BA, endsystolic values (n=266)



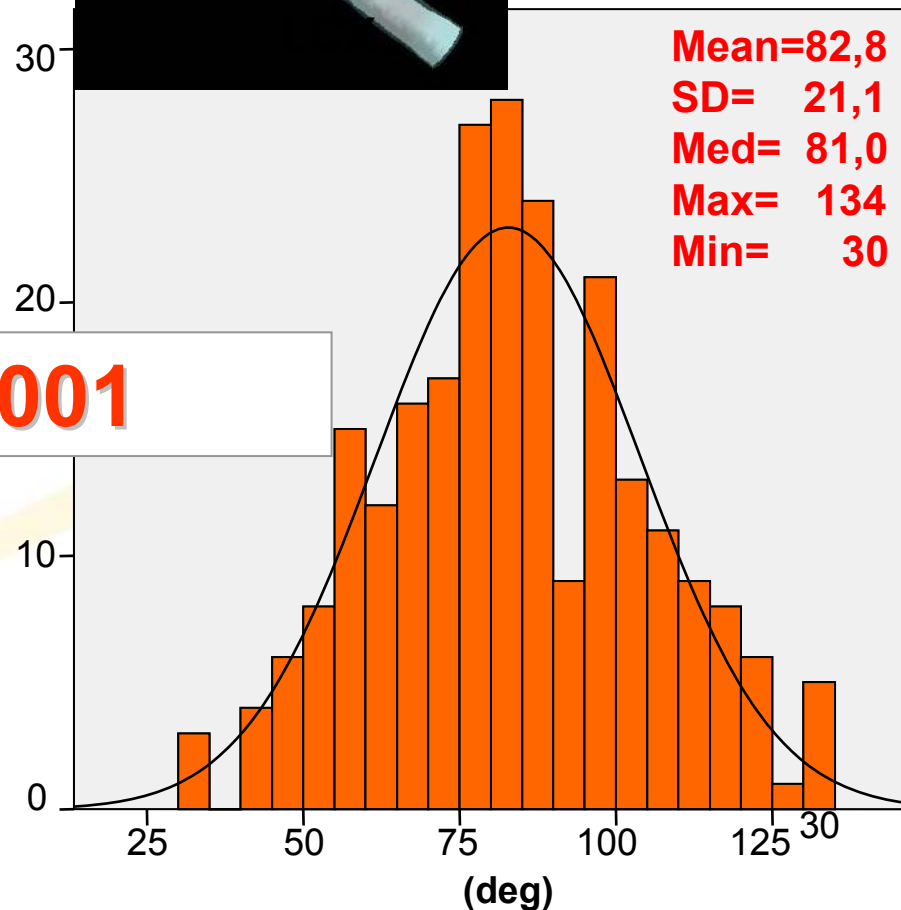
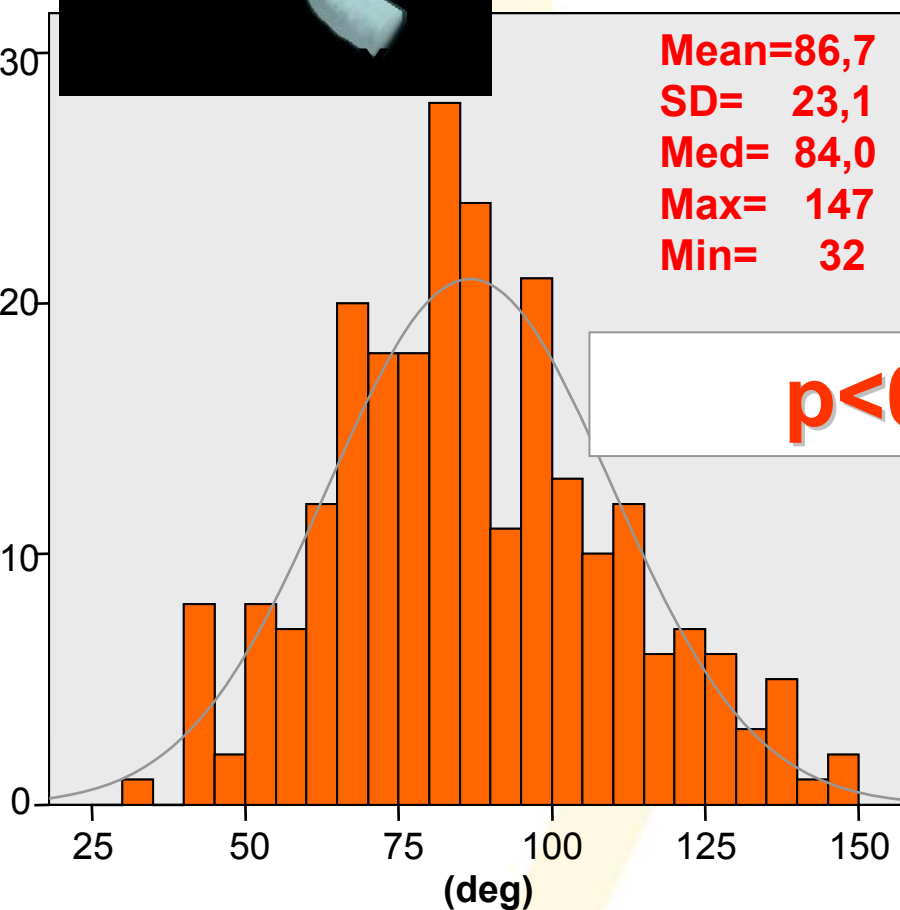
**Pre PCI**

Mean=86,7  
SD= 23,1  
Med= 84,0  
Max= 147  
Min= 32



**Post PCI**

Mean=82,8  
SD= 21,1  
Med= 81,0  
Max= 134  
Min= 30

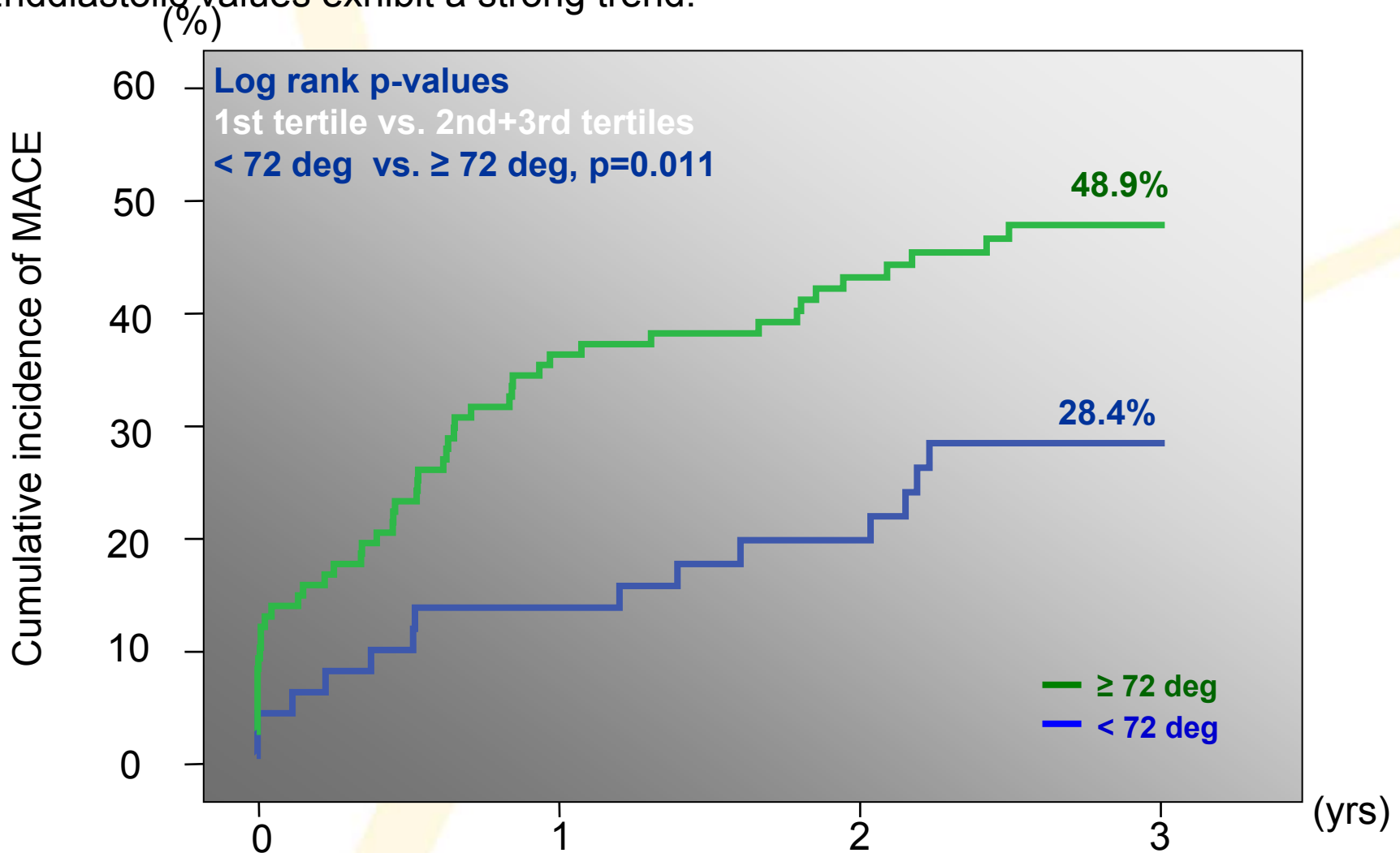




# MACE at 3 yrs-prePCI systolic BA

## Entire population TXC (n=157)

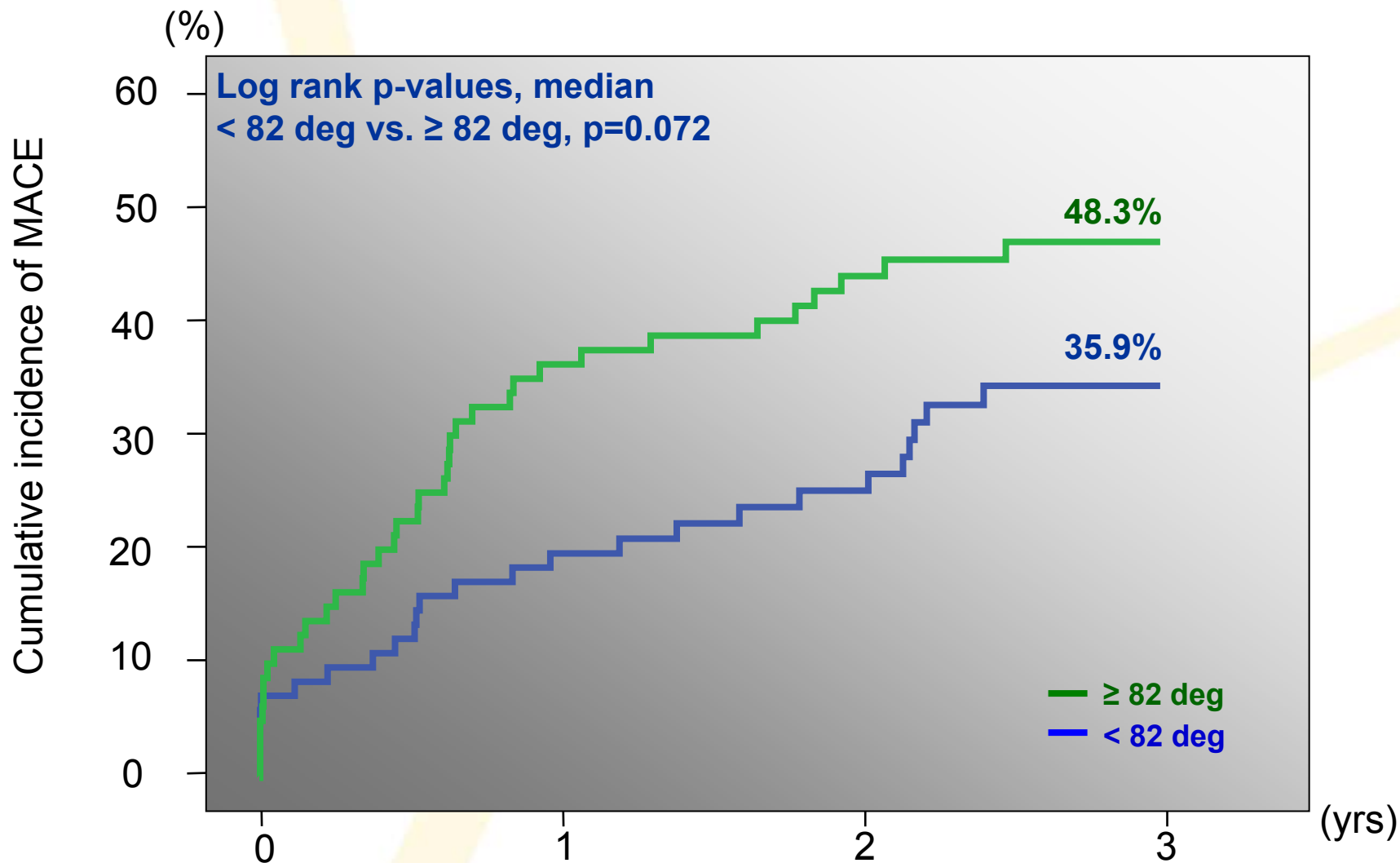
Endsystolic values of distal BA affect the outcome (MACE) significantly. This is the case both for the entire population as well as for subgroups( DES, distal LM treatment).  
Enddiastolic values exhibit a strong trend.





# MACE at 3 yrs-prePCI diastolic BA

## Entire population TXC (n=160)

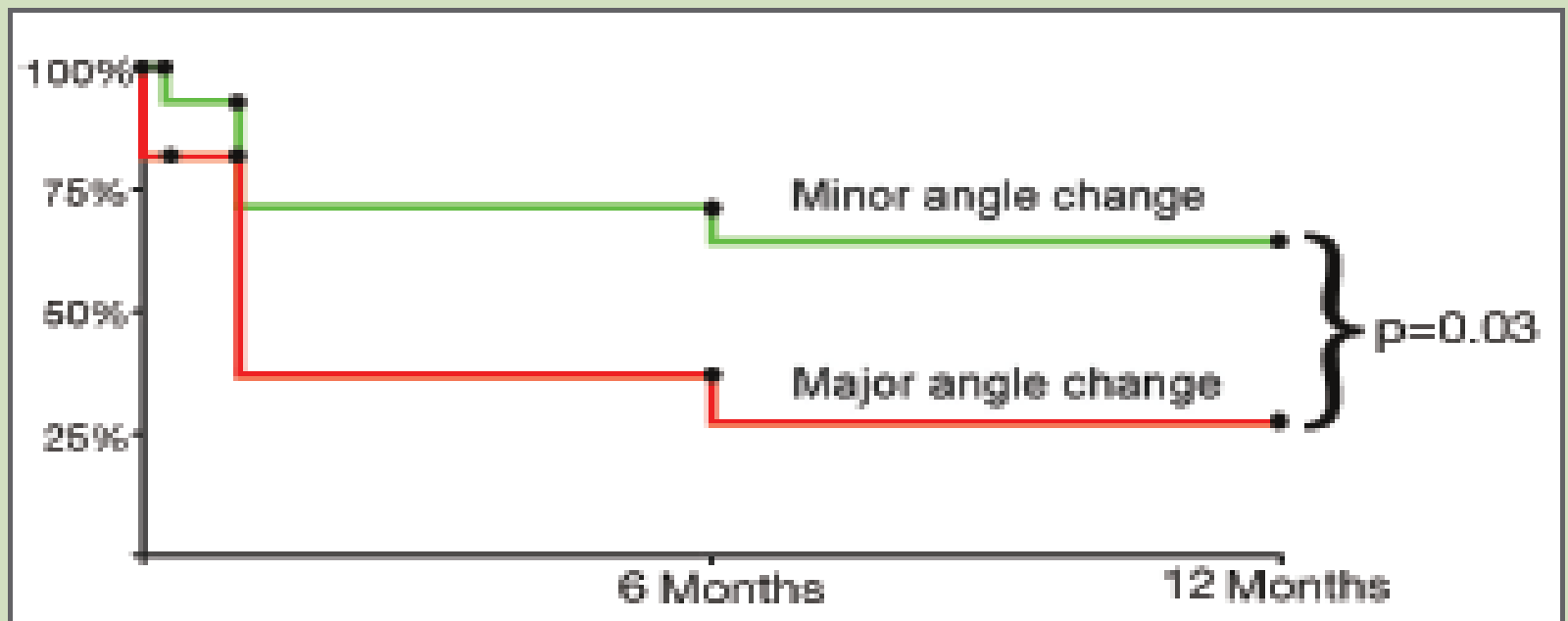


# RESULTS

## TVR free survival (%) according to absolute angle change after intervention

**Figure 2**

**MACE free survival**



Minor absolute bifurcation angle change: less than 20 degrees (n=42).

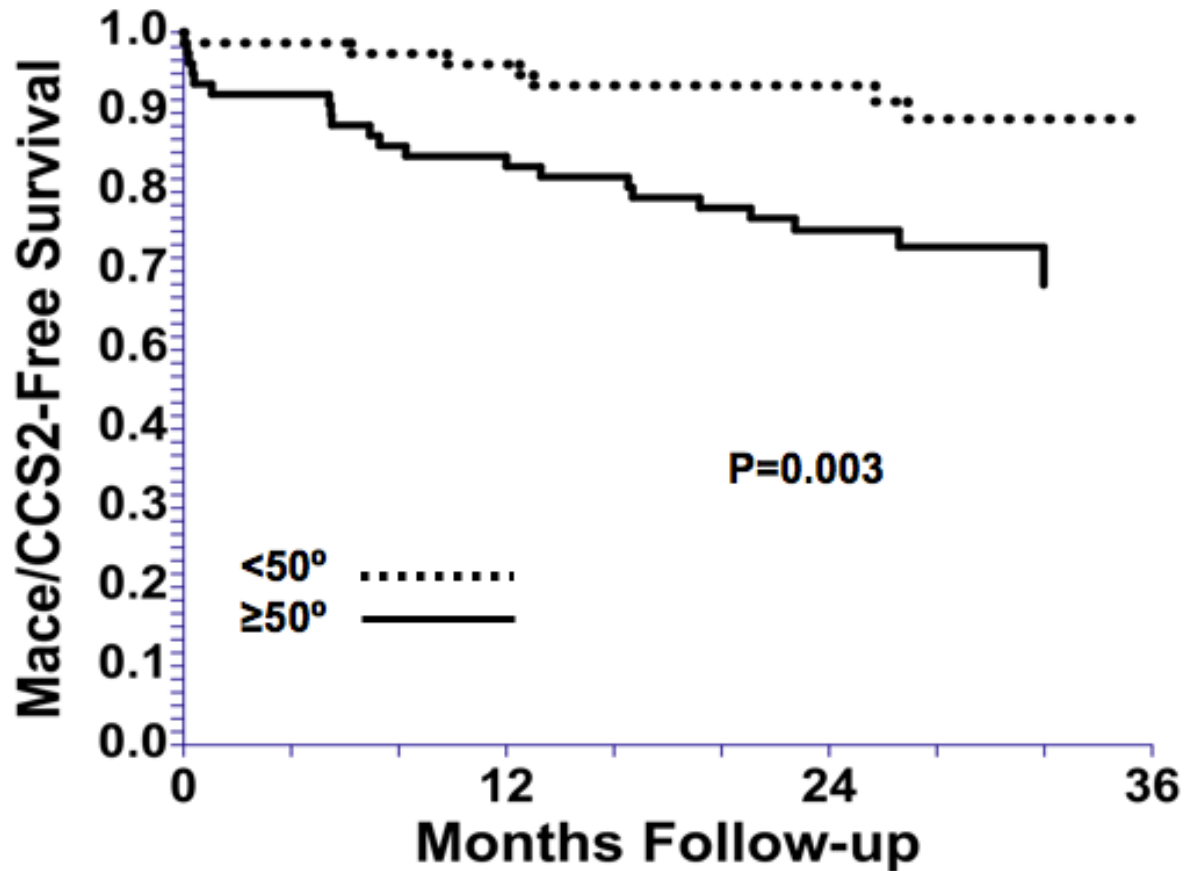
Major absolute bifurcation angle change: 20 degrees or more (n=11).



Figure 2b

# CRUSH (134)/CULOTTE(6) VS. MAIN VESSEL STENT ONLY: BIFURCATION ANGLE

Crush / Culotte



Collins et al. Am J Cardiol 2008;102:404 – 410

***0,1,0 LM LESIONS***

***LM STENTING OR NOT ?***

***YES***

***NO***

***Didier Carrié***

***Dr. Alfonso Medina***

*European Bifurcation Club*





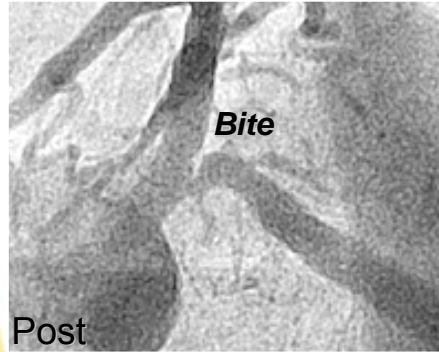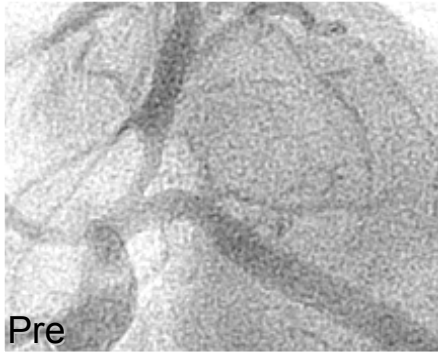# LM stenting- YES

## 0,1,0 LM LESIONS

- **Could safely be treated using a left main bifurcation technique**
- **Complete lesion coverage**
- **Final kissing balloon manage plaque shift and open stent struts**
- **Maximize blood flow into the adjacent « jailed » vessel**
- **Negative vascular remodeling may also result in progressive late narrowing of the adjacent vessel**
- **Ostial disease of the LAD behaves as a left main lesion when approached interventionally.**

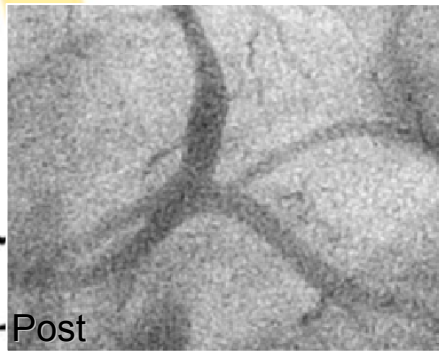
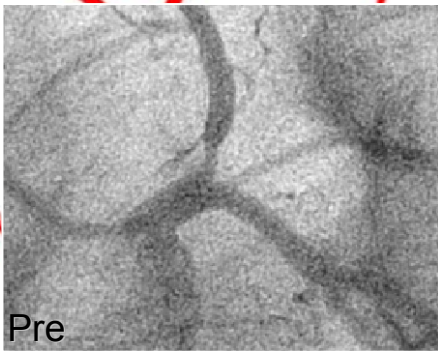# LCx damage (IVUS observations n=49)

## Vulnerable anatomy




Compromise 13/14  
(93%)

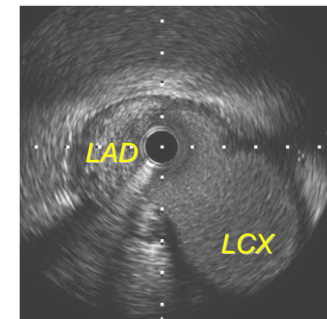
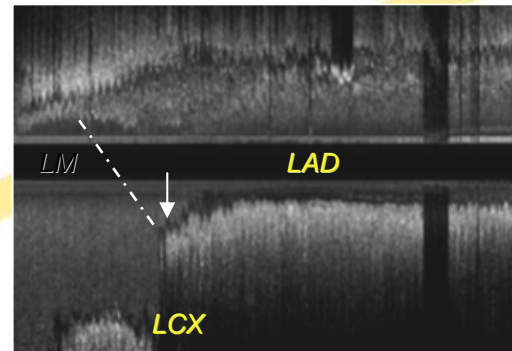
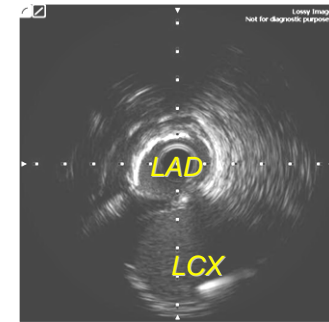
*European Bifurcation Club*



Compromise 1/35  
(3%)



**Eyebrow sign**





# **WHICH IS THE BEST STRATEGY for 0,1,0 LM LESIONS?**

- **Ostial disease of the LAD behaves as a left main lesion when approached interventionally in most cases.**
- **In cases with large bifurcation angle and IVUS documentation of absence of disease in distal left main a strategy with isolated ostial LAD stenting seems acceptable.**

**0, 0, 1 LESIONS**

**MAIN BRANCH STENTING OR NOT ?**

*European Bifurcation Club*

**YES**

**NO**

***P. Brunel***

***Dr. Alfonso Medina***

The logo for the European Bifurcation Club (EBC) features a stylized red heart shape with a white outline, positioned above the letters 'EBC' in a black serif font.

**EBC**



# WHICH IS THE BEST STRATEGY for 0, 0,1 LESIONS?

## NO Consensus

*At the moment two registries:*

'INVERTED' PROVISIONAL T

Ostium Stenting / Dogbone Technique



Thank you!