Welcome to the 8th European Bifurcation Club 12-13 October 2012 - Barcelona

Deployment in autopsy models

European Bifurcation Club

EBC

Dr. Stefan Kralev

I. Department of Medicine, Faculty of Medicine Mannheim, University of Heidelberg, Mannheim, Germany

European Bifurcation Club

EBC

Side branch occlusion after coronary stent implantation in patients presenting with ST-elevation myocardial infarction: clinical impact and angiographic predictors.
Kralev S, Poerner TC, Basorth D, Lang S, Wolpert C, Haghi D, Borggrefe M, Haase KK, Süselbeck T.
Am Heart J. 2006 Jan;151(1):153-7.

Natural history of small and medium-sized side branches after coronary stent implantation.
Poerner TC, Kralev S, Voelker W, Sueselbeck T, Latsch A, Pfleger S, Schumacher B, Borggrefe M, Haase KK.
Am Heart J. 2002 Apr;143(4):627-35

Why we started this study – published literature…

- FRONTIER stent registry reported an initial device success of 91%. At 6 month followup, the MACE rate was 17.1% with a main branch in-stent restenosis (ISR) of 25.3%.

  Lefèvre T, Ormiston J, Guagliumi G, Schultheiss HP, Quilliet L, et al. (2005), J Am Coll Cardiol 46(4): 592-598.

- Newer data evaluating the ML Frontier reported a device success of 95% (postprocedural main vessel stenosis 19%) with a follow-up ISR rate of 29% (in-stent late lumen loss 0.52±0.44mm).

  Radke PW, Jain D, Conrad A, Thomsen C, Remmel M, et al. (2008). Clin Res Cardiol 97(4): 260-265.

Why we started this study – other methods…

- We have IVUS, OCT, etc….so do we need microcomputed tomography assessment of stents ?
  - IVUS & OCT are performed when the stent is already implanted in the patient
  - *Evaluation in real atherosclerotic lesions* (in comparison to expansion of stents in waterbath or air)
  - MCT assessment can be ***performed before*** using the stent in real life patients, and ***detect problems before*** they occur in real life

Multi Link Frontier Stent

Abbott Vascular, Santa Clara, CA, USA



Porcine heart sample before stenting

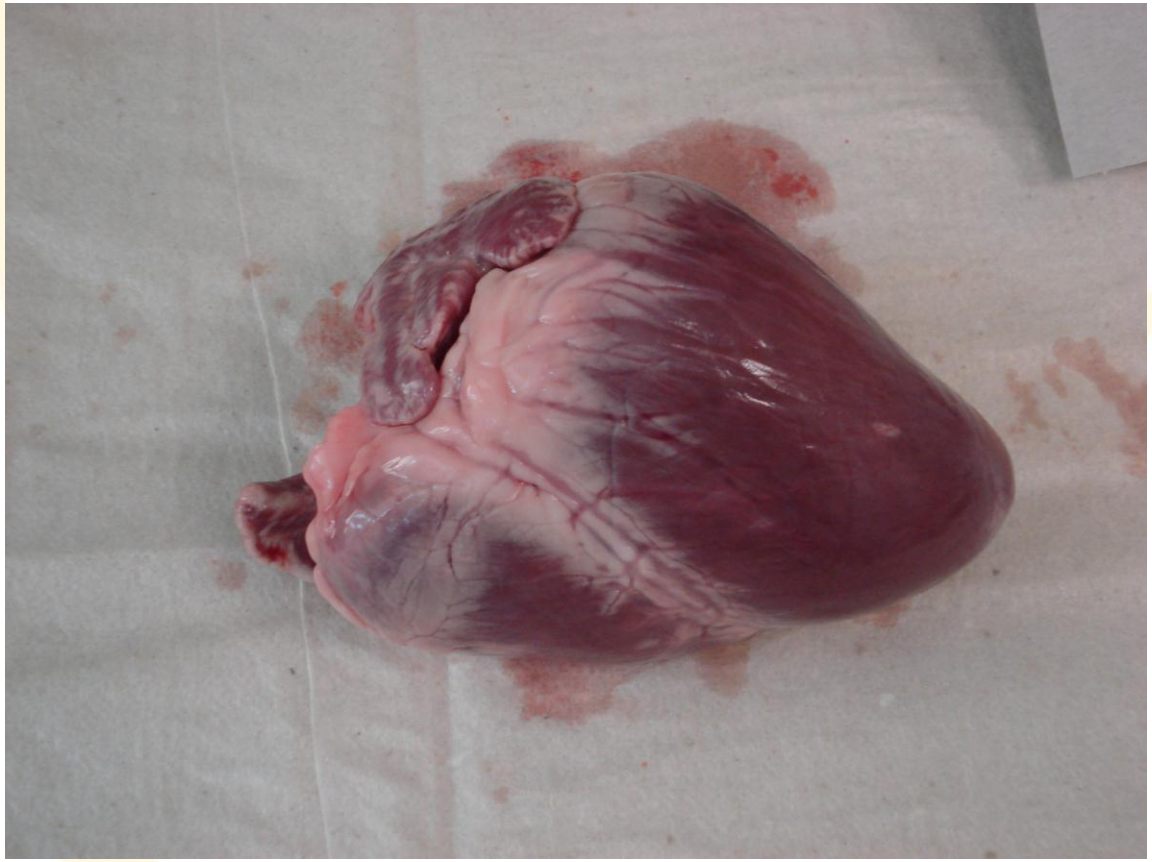

Preparation of heart samples

- Difficulties, Limitations & Problems
  - No aortic back up of the catheter
  - Fixing of the heart sample
  - No physiological coronary flow
  - Standard LAO /RAO projections not possible
  - Limited number of available human autopsy heart samples

Coronary angiography in heart samples

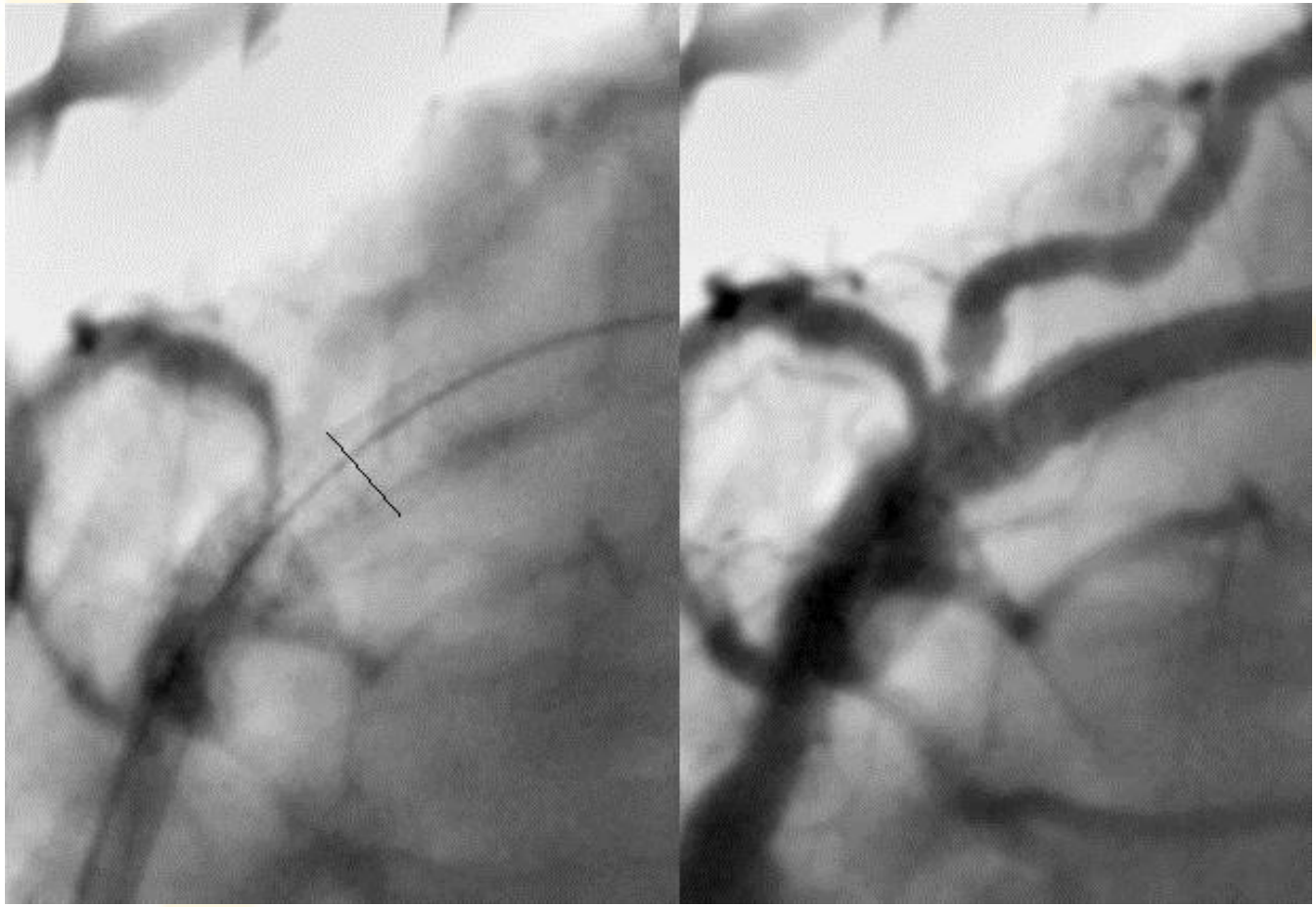

Porcine heart sample after stentimplantation

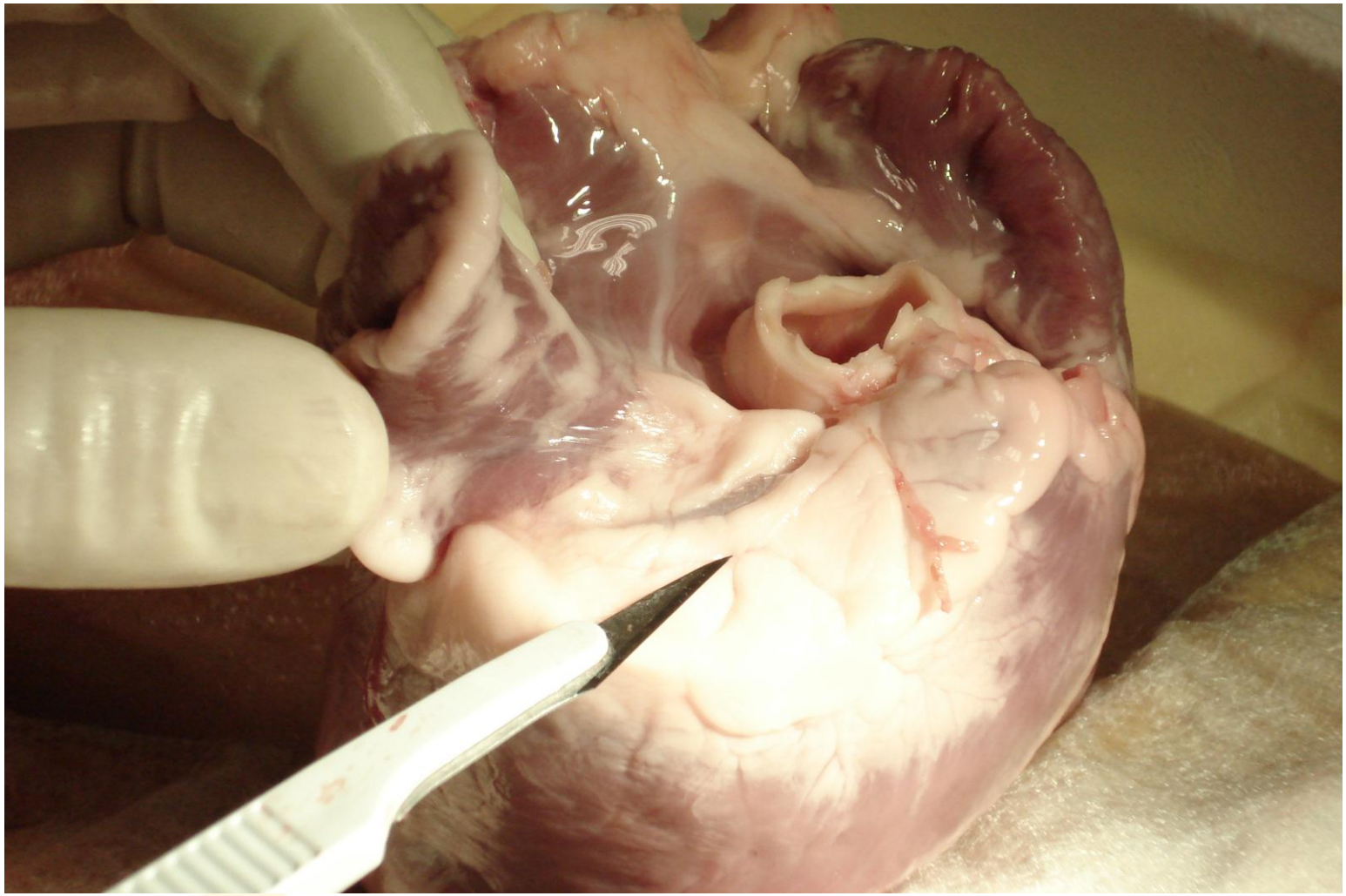

ML Frontier™ stent in porcine coronary artery

Kralev et al., PLoS One. 2011;6(7):e21778.

Heart sample in Falcon Tube prepared for Micro CT

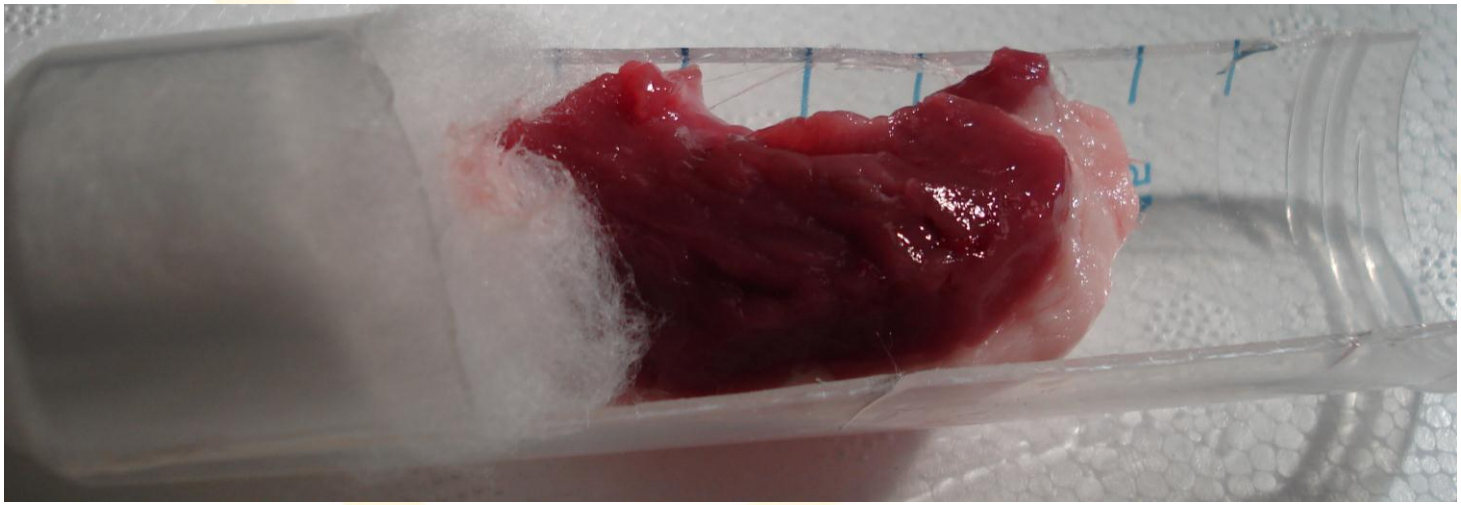

3D Visualization of the ML Frontier™ stent after expansion

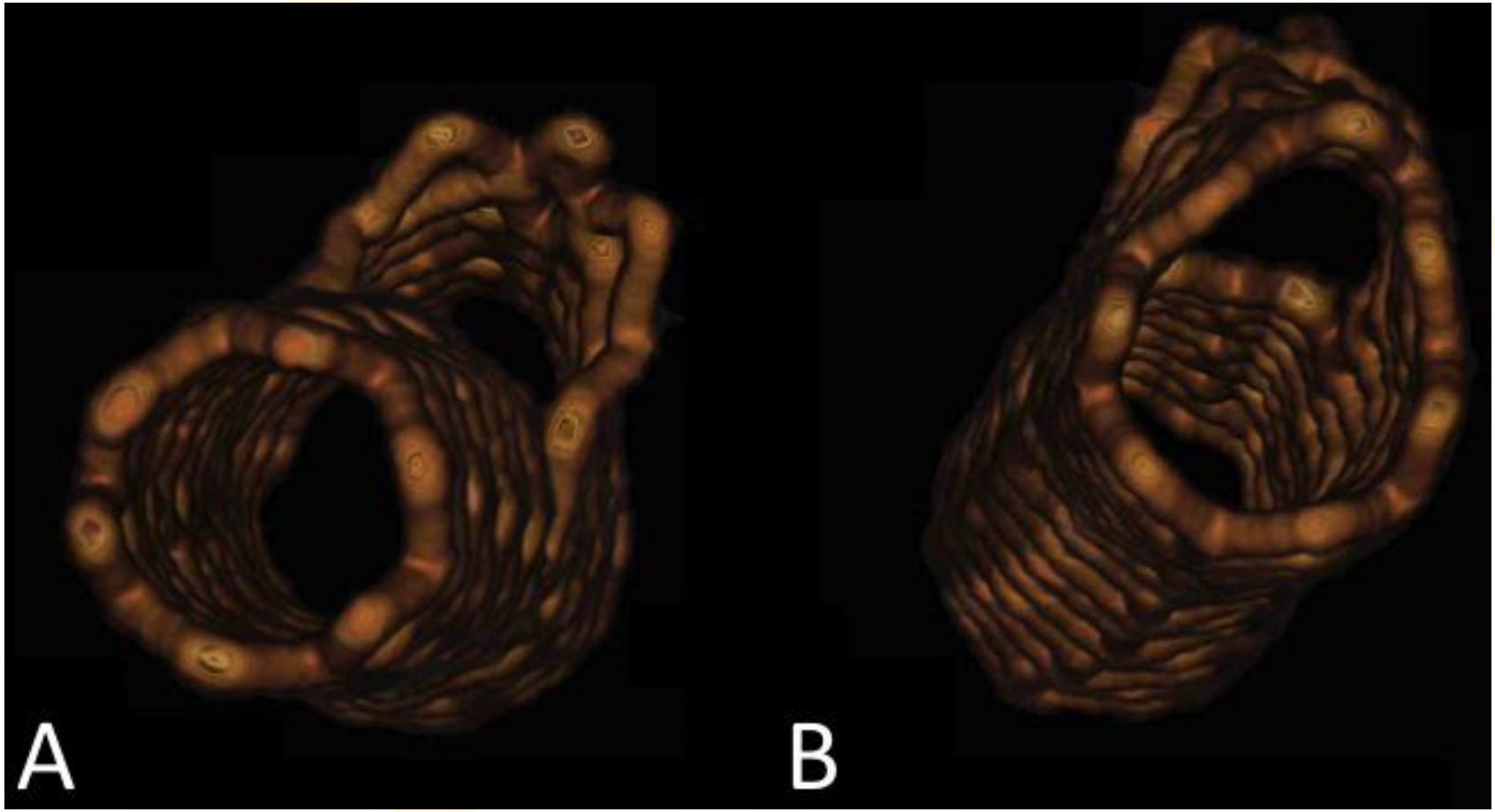

Kralev et al., PLoS One. 2011;6(7):e21778.

Assessment of the stent opening diameters and areas

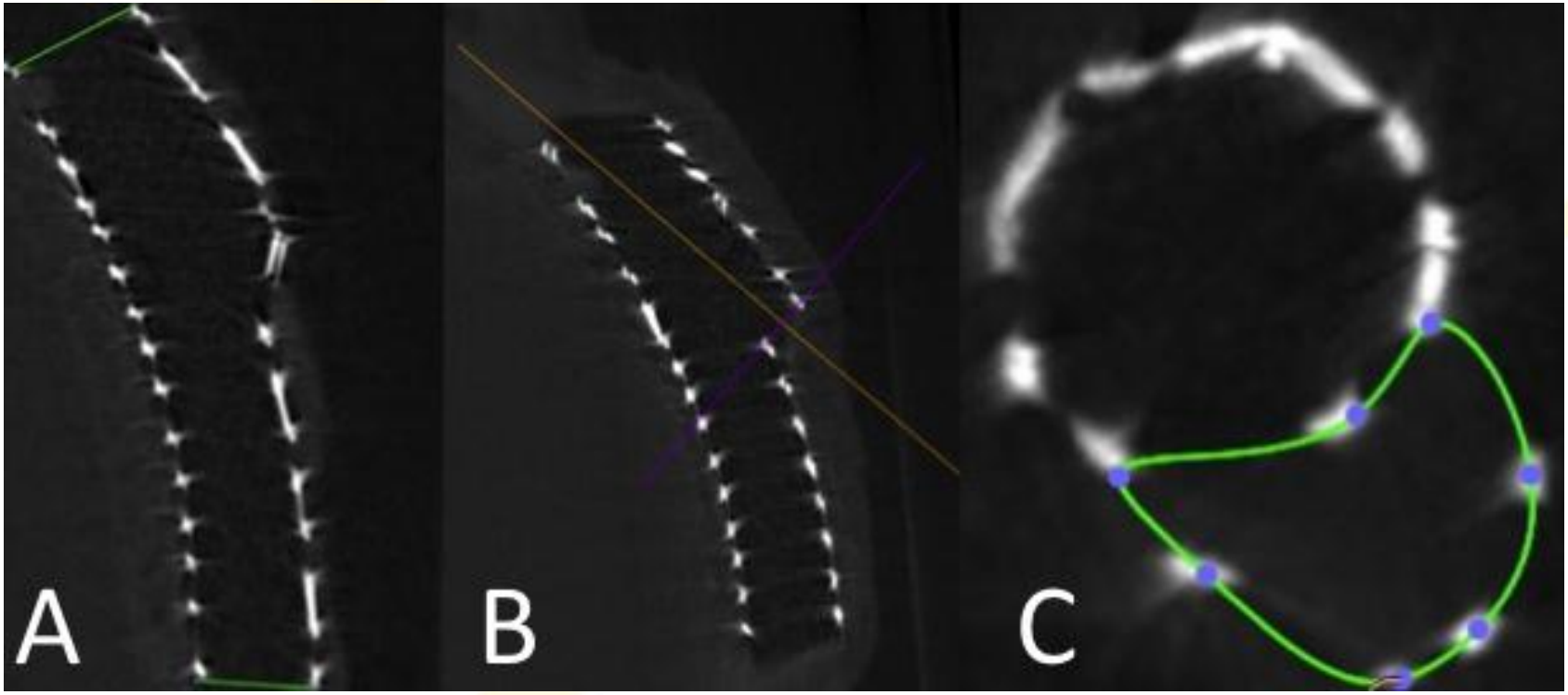

Kralev et al., PLoS One. 2011;6(7):e21778.

Assessment of the stent length

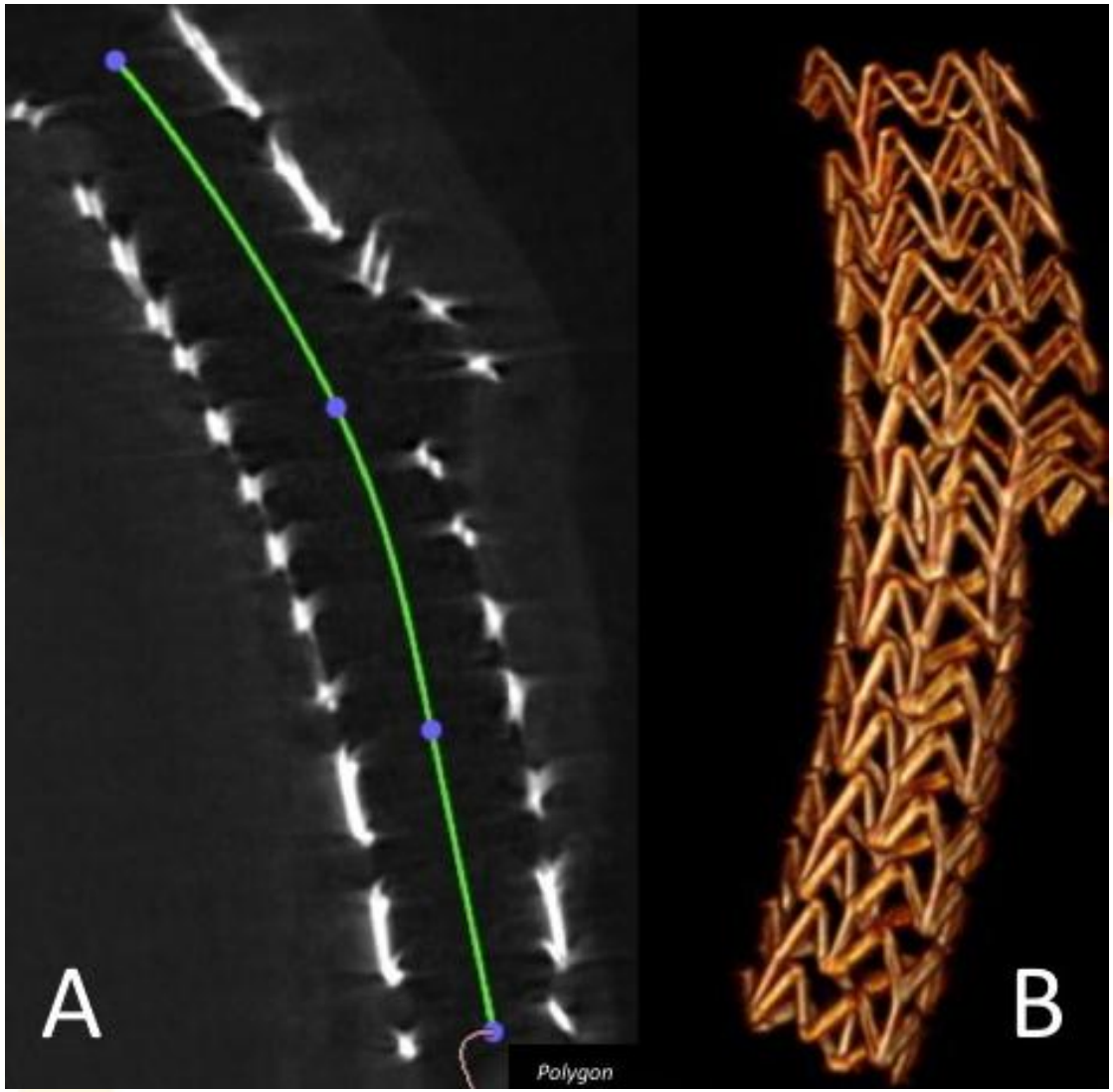

Kralev et al., PLoS One. 2011;6(7):e21778.

Comparison of stent areas between autopsy hearts, porcine model and data given by the manufacturer

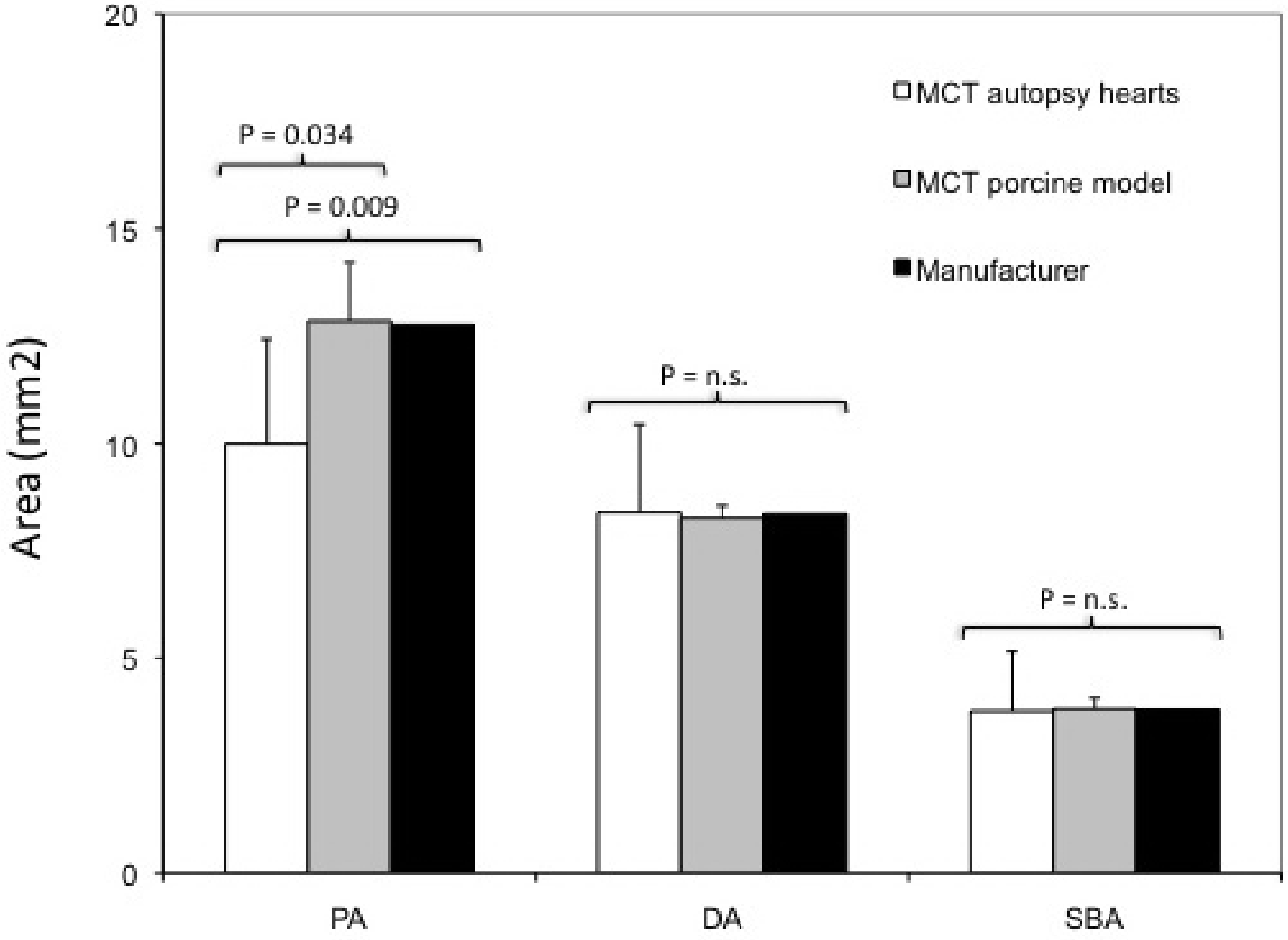

Kralev et al., PLoS One. 2011;6(7):e21778.

Conclusion

- *Micro-CT in autopsy heart samples* is a feasible tool for exact surveying of dedicated stent systems

  in *real atherosclerotic lesions* (in comparison to expansion of stents in waterbath or air)

  and could make a *contribution to the development* of new stent systems

Kralev et al., PLoS One. 2011;6(7):e21778.