Antonio L. Bartorelli
Centro Cardiologico Monzino IRCCS
Institute of Cardiology
University of Milan

Tryton Bifurcation Stent: Basic Concepts and Initial Clinical Experience

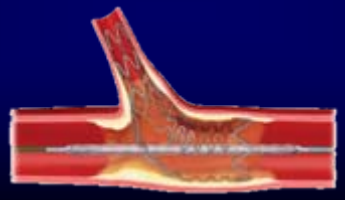

4th EBC Meeting
Prague
September 26-27, 2008

Bifurcation Coronary Lesions

- Restenosis of bifurcation lesions remains high even in the DES era, particularly wiht the two-stent technique
- Crush-stent technique offers complete coverage of SB but postprocedural IVUS imaging showed*:
  - MSA significantly smaller in SB than in MV
  - SB stent frequently underexpanded, tipically at the ostium
  - MSA of SB <4 mm^2 in 55%, <5 mm^2 in 90%
  - Incomplete SB or MV stent apposition in the crush area (60%)
  - Stent underexpansion not detected by angiography

Costa et al. JACC 2005;46:599-605

Dedicated Bifurcation Devices

	Balloon Expandable	Self-Expandable
Side Branch	• Tryton 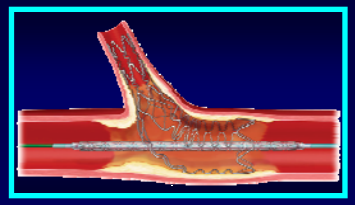	• Cappella 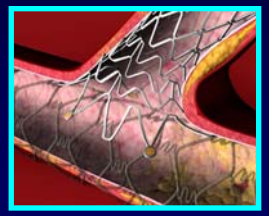
Main Vessel	• Petal	• Devax 
	• Frontier 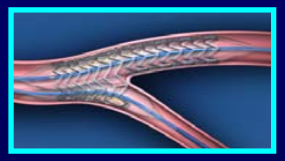	
	• Invatec Twin Rail	• Stentys 
	• TriReme 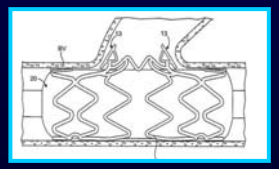	

Tryton Side-Branch Stent Hybrid BMS/DES Strategy

- Hybrid Strategy
  - Tryton Side-Branch Stent: Bare Metal Stent (CoCr)
  - Main Vessel: Drug-Eluting Stent

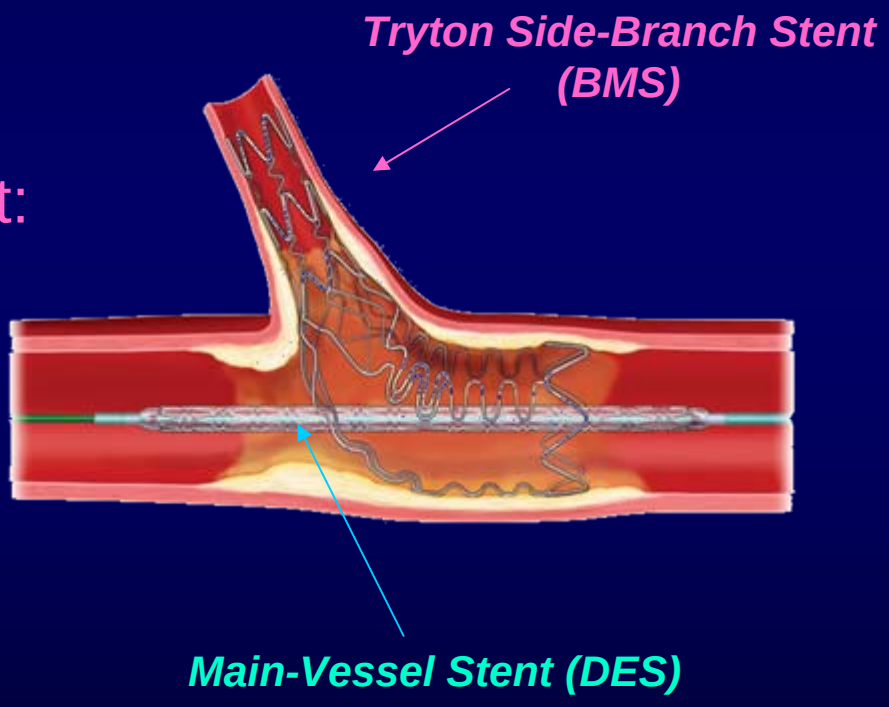

Tryton Side-Branch Stent

Slotted-tube balloon-expandable stent

Side-Branch Region
Standard Design
(6 mm)

Transition Zone
Coverage
Hoop Strength
(4 mm)

Main-Vessel Region
Three Fronds
Minimal Coverage
Wedding Band
(8 mm)

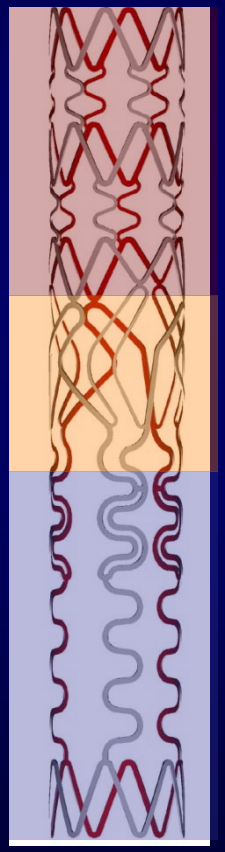

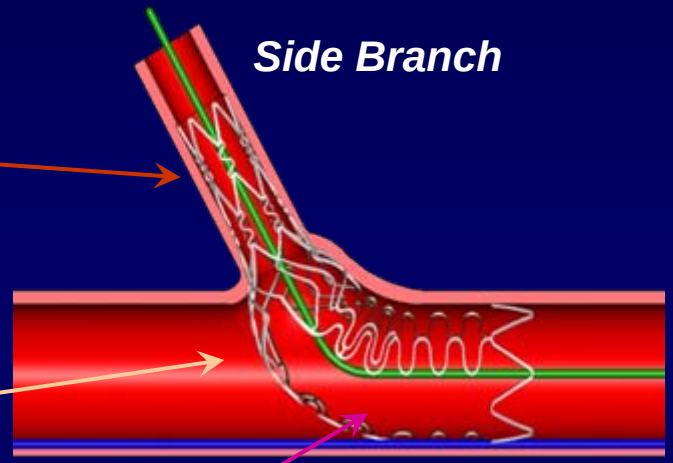

Tryton Stent and Delivery System

Stent Border Markers (19 mm)



Straight Balloon (2.5 mm)

Transition Zone Markers (4 mm)

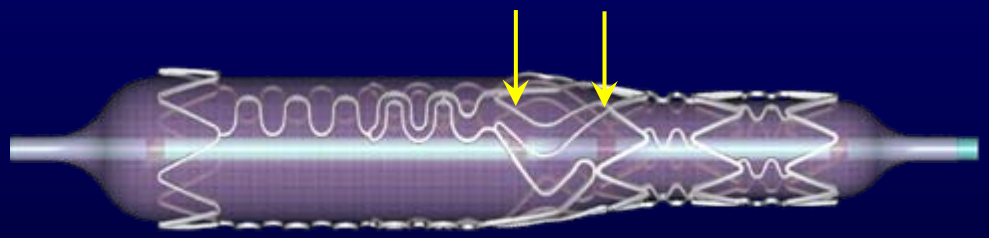

Stepped Balloon (3.5>2.5 mm)*

*** 3.5>3.0, 4.0>3.0, 4.0>3.5 mm soon available**

STENT CHARACTERISTICS

- Cobalt Chromium alloy
- Strut thickness= 0.0033" (85 µm)
- Stent length= 18 mm
- Angles: all
- Generous landing zone
  (positioning tolerance)

DELIVERY SYSTEM

- Rapid exchange catheter
- Single-wire tracking
- No need for rotational orientation
- Low Profile
  - 5Fr guide compatible
- Balloon
  - Semi-compliant
  - Rated burst= 14 atm

1. Position SB Stent

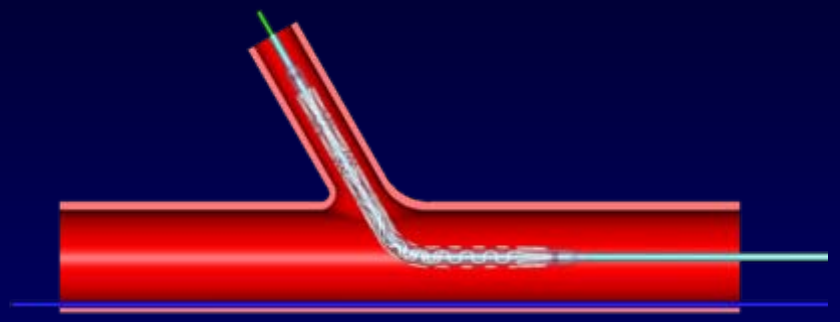

2. Deploy SB Stent

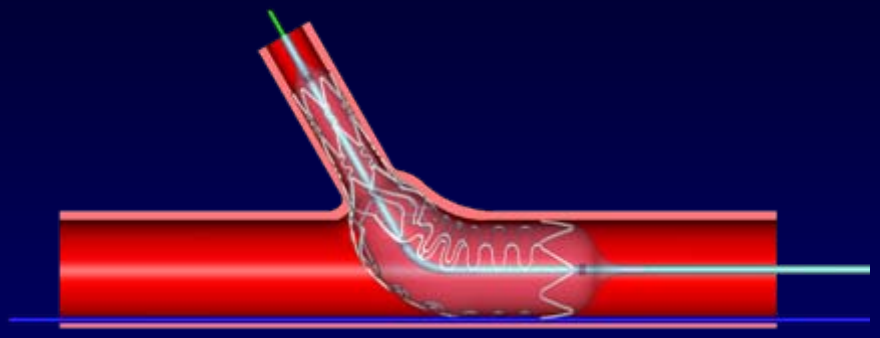

3. Position MV Stent

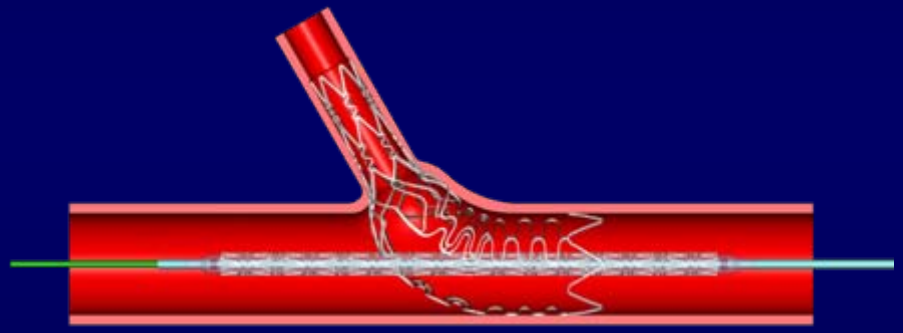

4. Deploy MV Stent

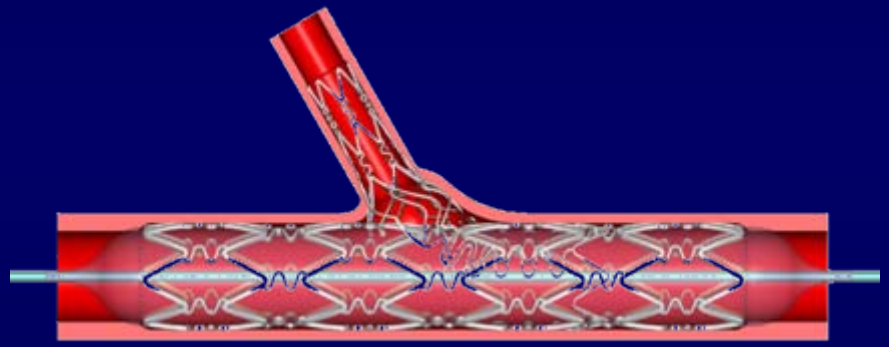

5. Postdilate SB + Kissing

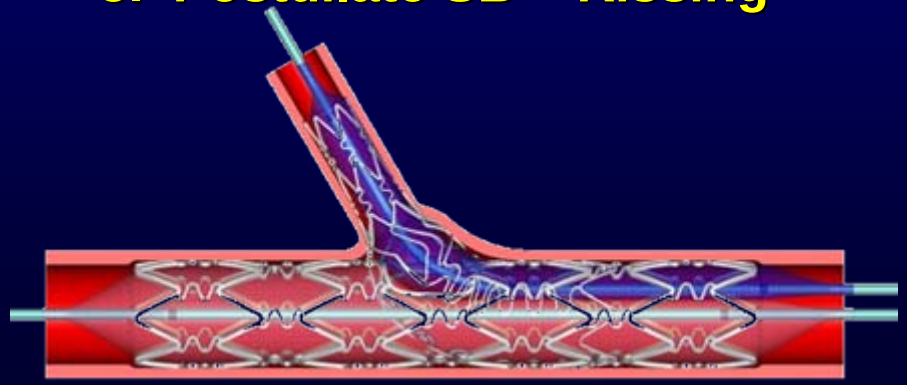

6. Procedure Complete



Tryton I (FIM): 6-month Follow-Up

Complex LAD-D1 Lesion

Baseline

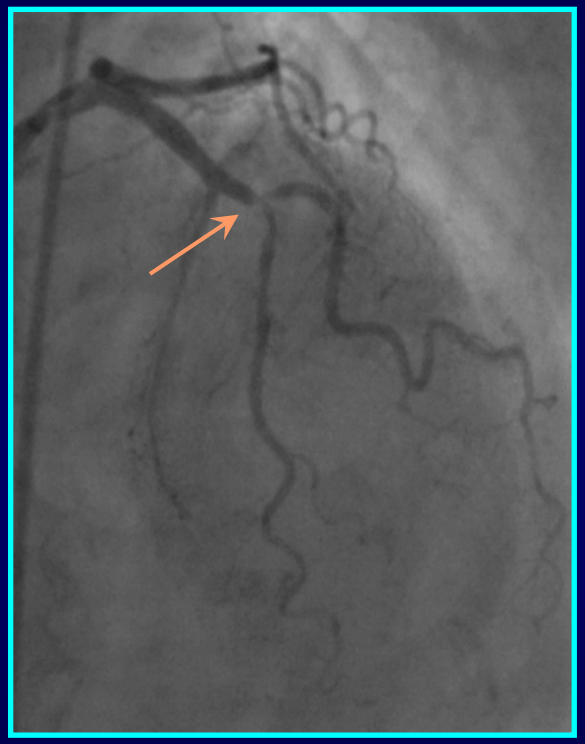

- High-Grade Lesion
  - Mid LAD-Diag
  - Medina (1,1,1)

Post Procedure

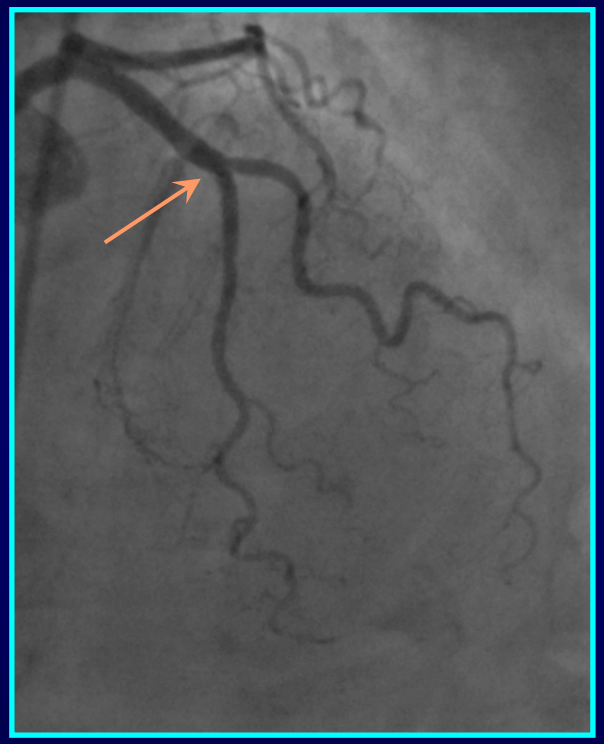

- Procedural Success
  - Diag Stent: Tryton
  - LAD Stent: Cypher

6-Month F/U

- No Restenosis

Onuma et al. Eurointerv 2008;3:546-552

Tryton I (FIM): Target Vessel

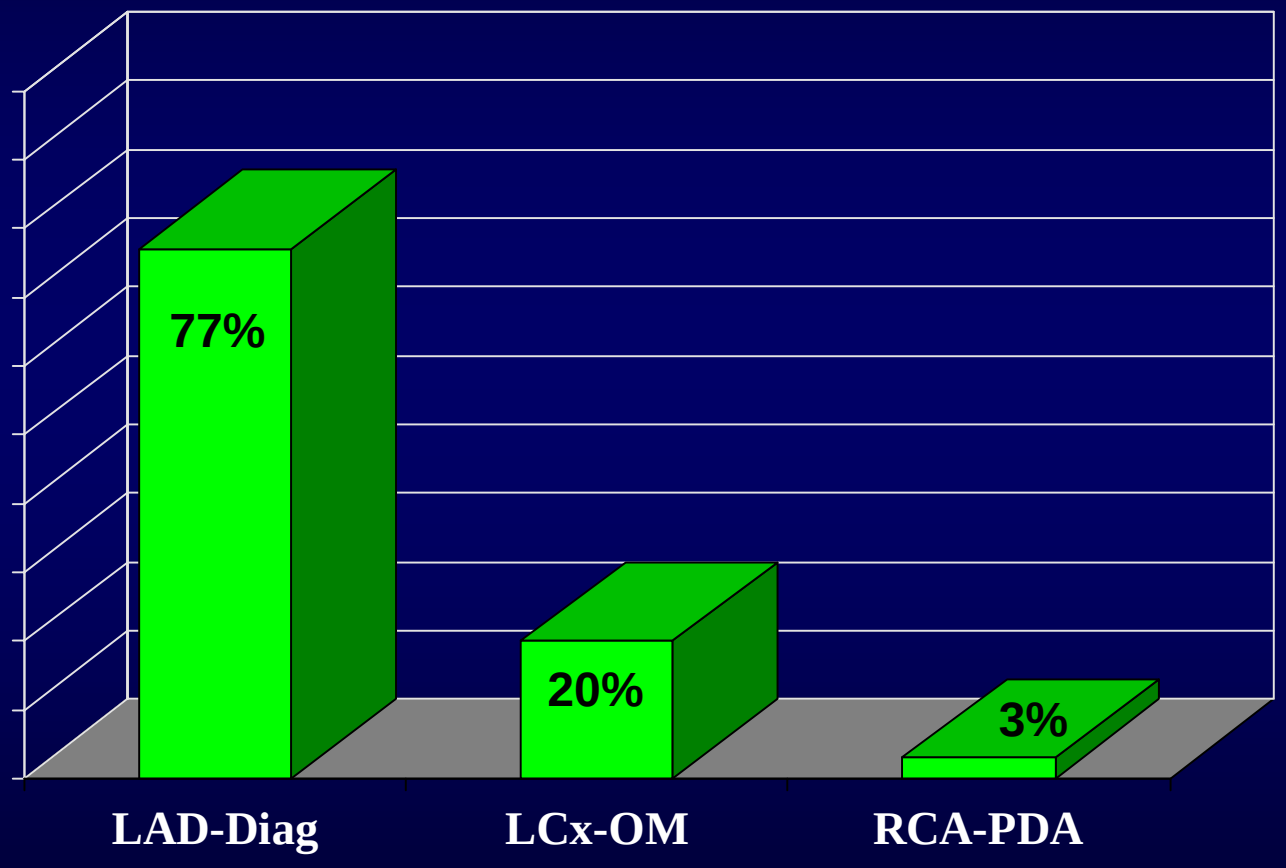

Onuma et al. Eurointerv 2008;3:546-552

Tryton I (FIM) Study

- Procedural Technique
  - 6 Fr. guide catheter: 97%
  - MV DES (30 Cypher and 9 Taxus stents)
  - Final kissing balloon inflation: 100%
- Acute Results
  - Angiographic success : 97% (29/30)
  - Procedural success: 93% (28/30)
- 6-Month Clinical F/U (n=30)
  - No stent thrombosis
  - MACE: 10% (not Tryton related)
    - TLR: 1 (3%) - proximal MV restenosis
    - TVR: 3 (10%) – all MV
    - Side branch failure: 0 (0%)
- 6-Month angiographic F/U (n= 23 [79%])
  - Late Loss at 6 months
    - Proximal MV: 0.25 ± 0.43 mm
    - Distal MV: 0.00 ± 0.31 mm
    - Side branch: 0.17 ± 0.35 mm

Hybrid Approach

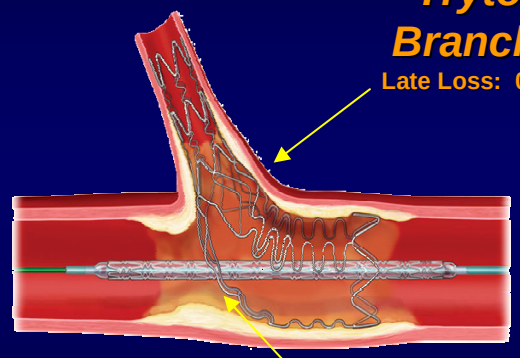

Onuma et al. Eurointerv 2008;3:546-552

Long-Term Follow-Up

	Discharge	N=30 6 month FU	9 month FU
Death	1	1	1
MI	1	1	1
CABG	0	0	0
TLR	0	1	1
TVR	1	3*	3*
MACE (Hierarchical)	2	3	3

No additional events from 6-M to 9-M

**All three TVRs are not Tryton Stent related.*

1st TVR - the patient did not receive a Tryton stent incurred death

2nd TVR - resulted from a 90% restenosis of the proximal edge of the Main Branch Stent

3rd TVR - resulted from a distal MB intervention, not at the site of the bifurcation

Possible Explanations of the Remarkable Tryton I (FIM) Study Results

- The very low late loss of Tryton stent could be due to drug elution from the main vessel DES
- SB restenosis might also be prevented by the large MSA, the complete stent expansion and the full coverage of SB ostium
- The latter hypotesis needs to be clarified with an IVUS study

Tryton II – The IUVANT Study

*I*ntravascular *U*ltrasound E*va*luatio*n* of *T*ryton Stent

- Single-center prospective study (n=30 patients)
- Six-month angiographic and IVUS F/U
- Postintervention and F/U IVUS analysis in both branches
- 40-MHz IVUS catheter (BSC) advanced 10 mm beyond and proximal to the stented segmentsl
- IVUS imaging recorded during automated transducer pullback (0.5 mm/s) onto a CD rom for off-line analysis

Tryton II – The IUVANT Study

*I*ntravascular *U*ltrasound E*va*luatio*n* of *T*ryton Stent

Target Vessel

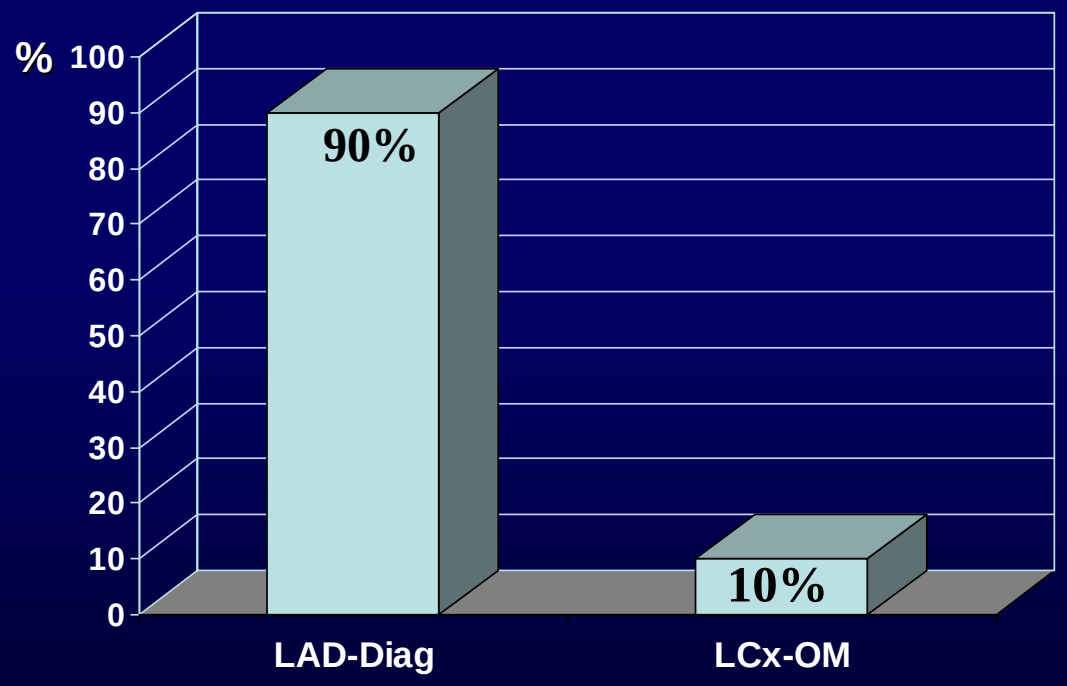

Tryton II – The IUVANT Study

***I*ntravascular *U*ltrasound E*va*luatio*n* of *T*ryton Stent**

Preliminary results

- 10 patients (7 men, 3 women, mean age 66±11 yrs)
- 9 LAD-Diag and 1 CFx-OM
- All Tryton stents correctly implanted in SB and all DES (Xience V) properly placed in MV
- Kissing balloon performed in all cases
- 100% angiographic and procedural success
- IVUS imaging of all SB and of 9/10 MV

Tryton vs. Crush Postprocedural IVUS

CRUSH *

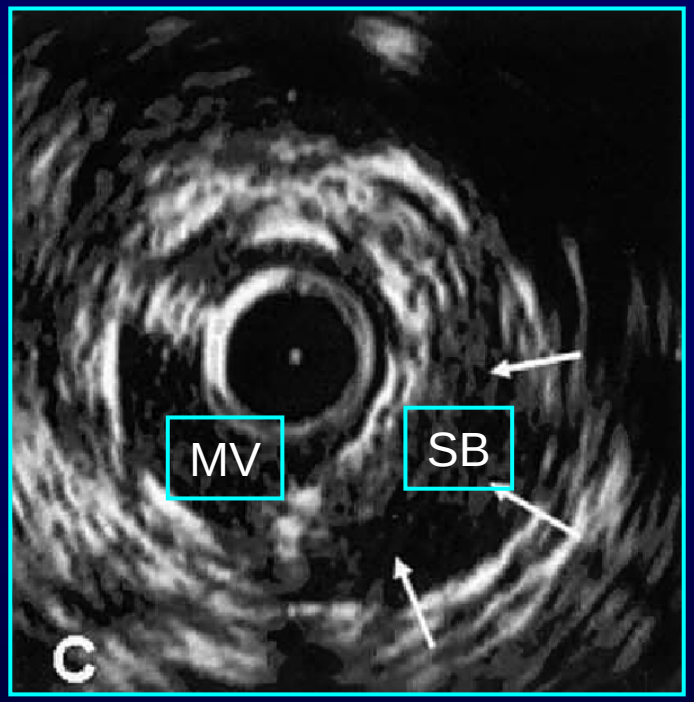

TRYTON

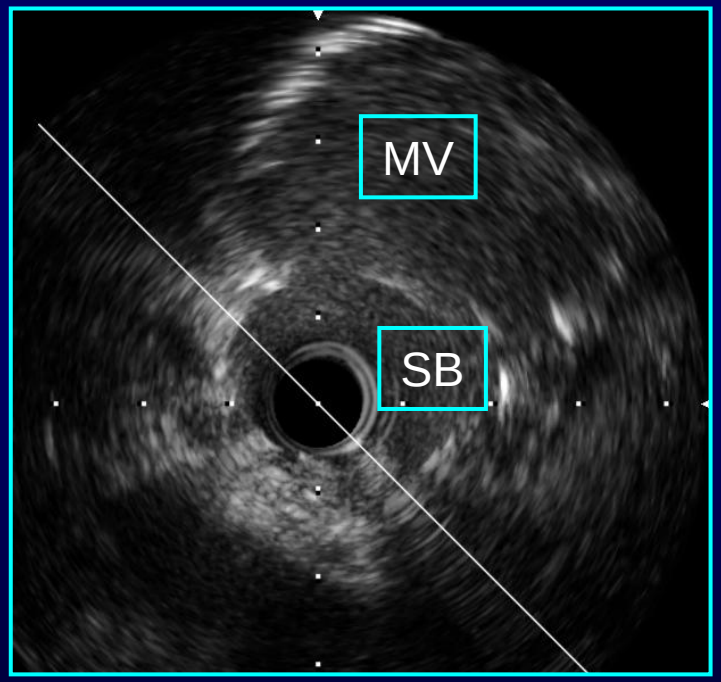

* Costa et al. JACC 2005;46:599-605

Tryton vs. Crush
Postprocedural IVUS Data

	Tryton *n=10*	CRUSH *# *N=15*
SB ostium MSA	4.71 ±1.05	4.2 ± 1.0
SB distal MSA	4.45 ±1.1	4.5 ± 2.3
SB Stent CSA <4 mm^2	21%	55%
SB Stent CSA <5 mm^2	66%	90%
SB Dmin/Dmax	0.83	N/A

#Non-LM lesions

* Costa et al. JACC 2005;46:599-605

Conclusions

- When used in conjunction with a DES, the Tryton stent is associated with good clinical outcome and low restenosis rate
- These preliminary IVUS results show:
  - Complete coverage of side branch ostium
  - Complete stent expansion
  - Large final area
  - High symmetry (Dmin/Dmax) of the Tryton stent
- This may contribute to the low restenosis observed in Tryton I
- These preliminary data suggest that the Tryton stent approach provides a reliable and reproducible strategy to stent the SB and its origin