Intra-procedural, sequential OCT imaging to guide the treatment of complex bifurcation lesions with dedicated stent and BVS

European Bifurcation Club
18-19 October 2013

Joanna Wykrzykowska, MD PhD
Academic Medical Center, Amsterdam, the Netherlands

Case:

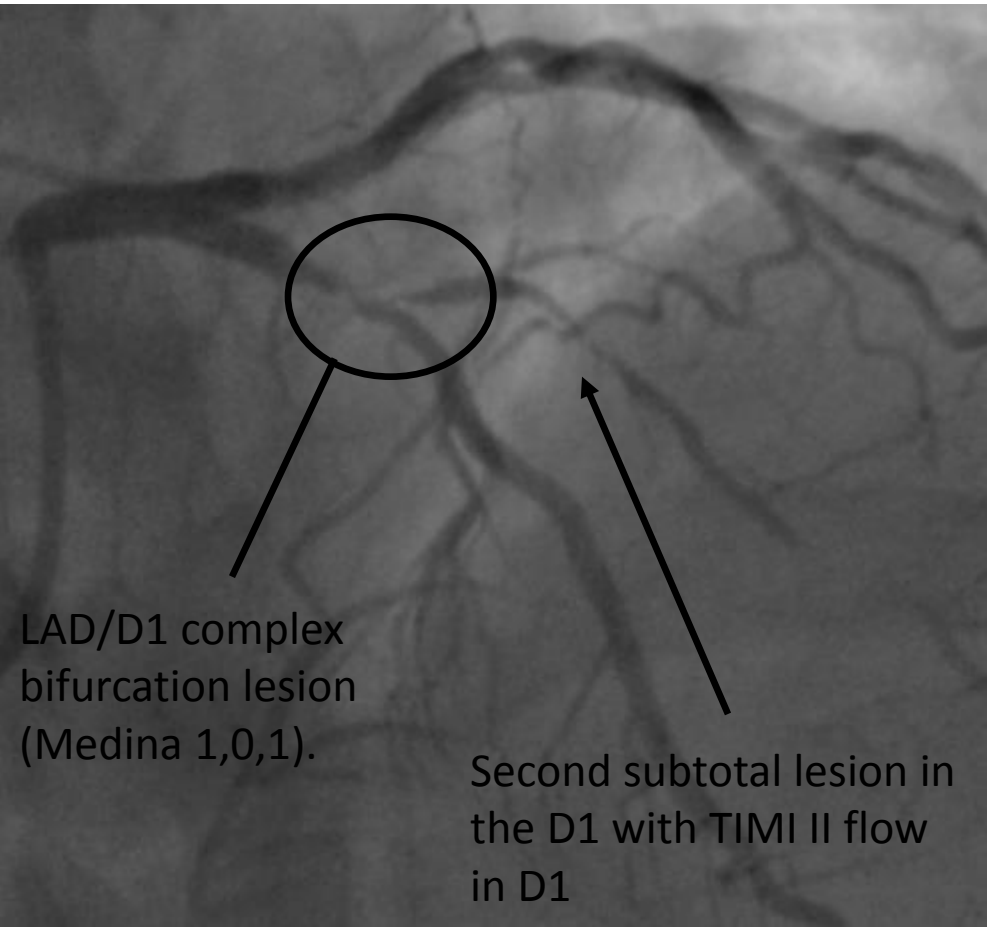

Treatment strategy:

ABSORB in distal D1, Tryton/ABSORB LAD/D1 bifurcation

- Tryton procedure could be considered as a 'facilitated Culotte'
- In this case, we performed 3 OCT pullbacks
  - 1st (D1-> prox LAD)after BVS and Tryton placement
  - 2nd (distal -> prox LAD) after rewiring side branch wire into the distal MB through Tryton
  - 3rd (distal -> prox LAD) after final resut

1st run (D1->prox LAD after Tryton):

Consecutive distal-to-proximal OCT still frames show no device overlap

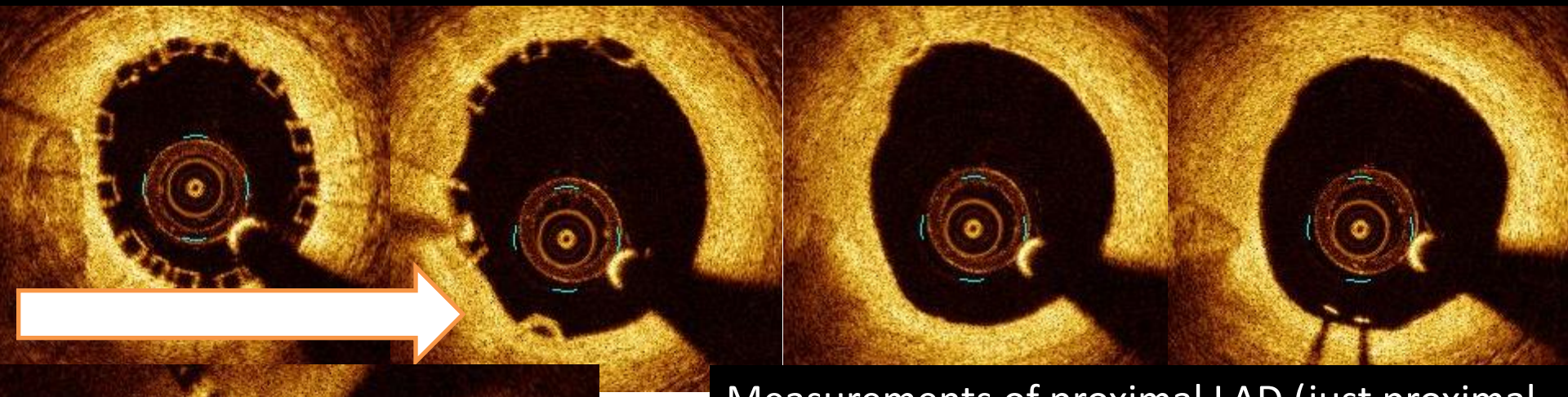



Measurements of proximal LAD (just proximal of Tryton) allowed us to choose an appropriate sized ABSORB stent as MB stent

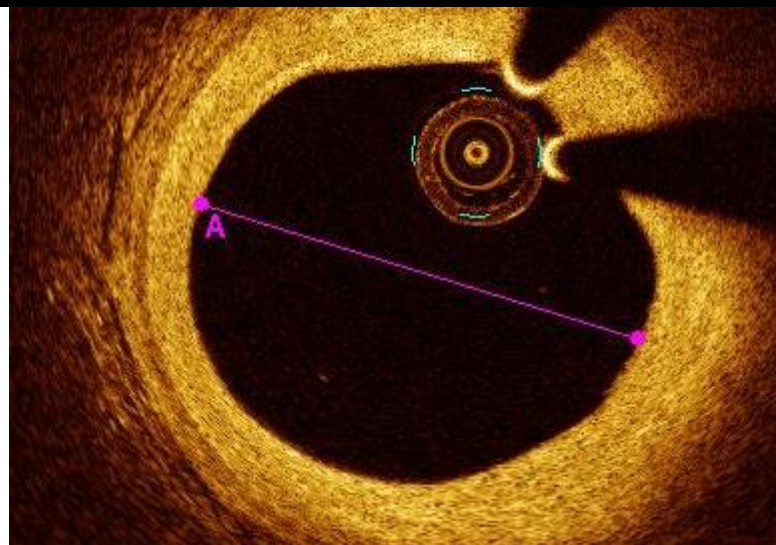

The relative position of the Tryton stent in front of the distal MB 'ostium' is difficult to assess with 2D OCT

Which is confirmed at the area of the three fronds ('*')

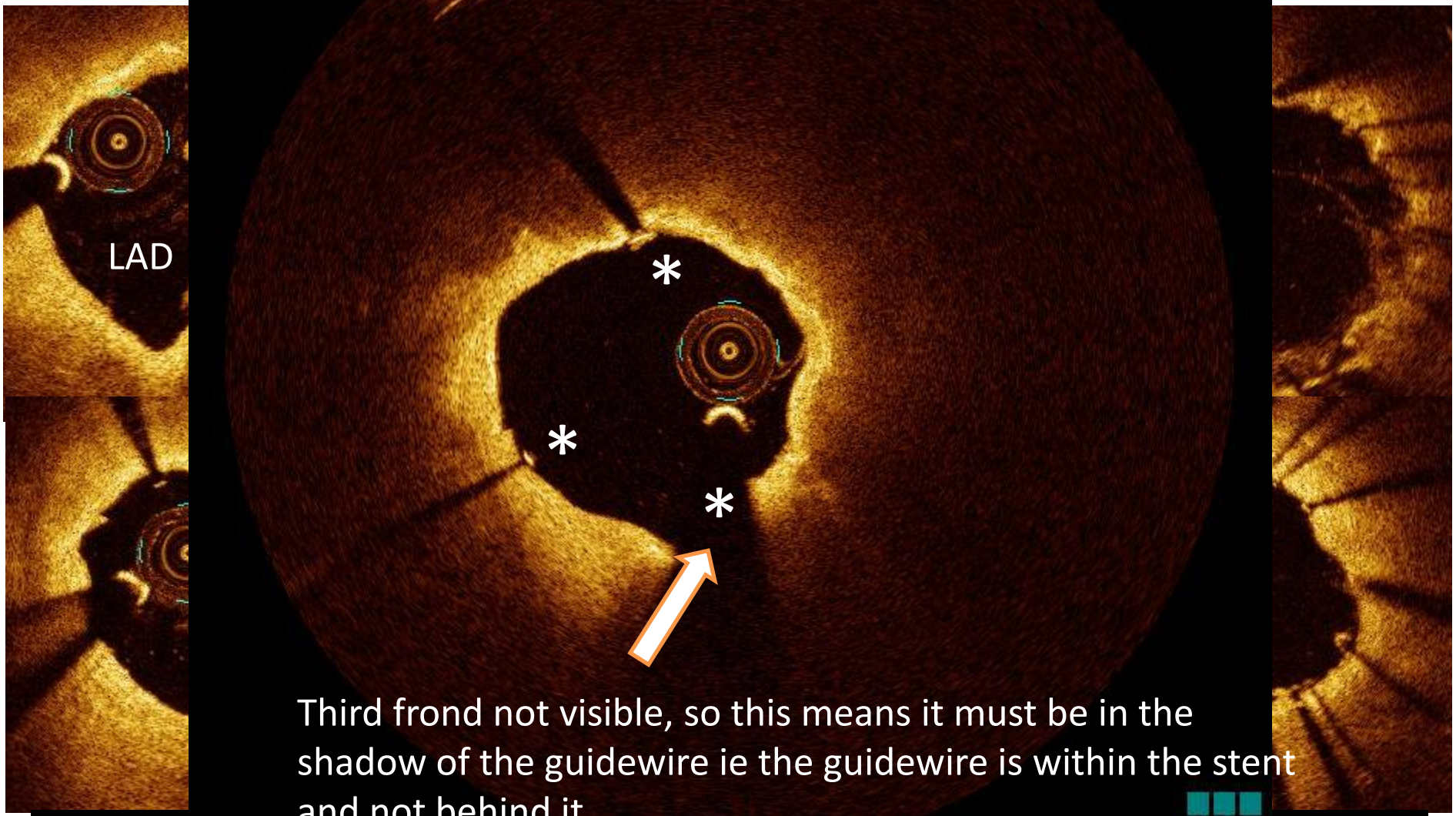

Third frond not visible, so this means it must be in the shadow of the guidewire ie the guidewire is within the stent and not behind it

Consecut
Tryton st

f the
re

3rd run: after MB stent placement

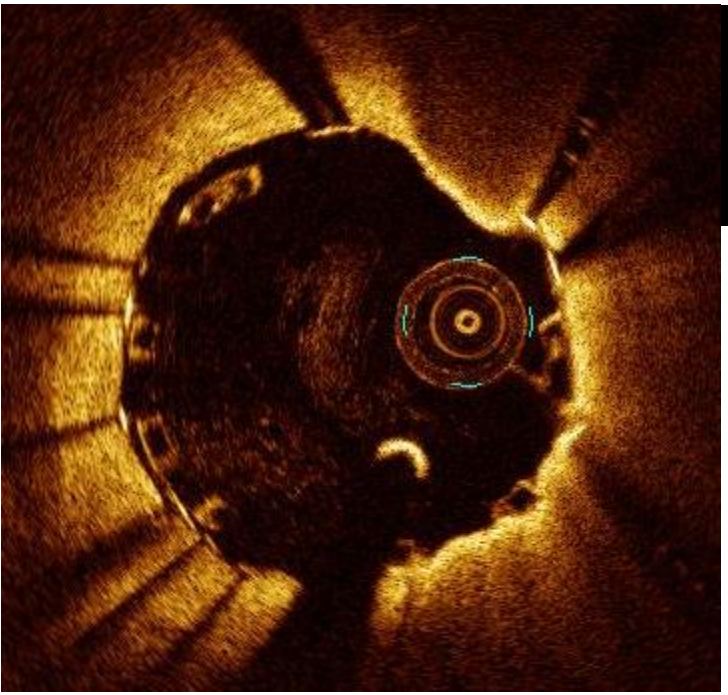

To assess adequate stent deployment and apposition, especially in the overlapping region.

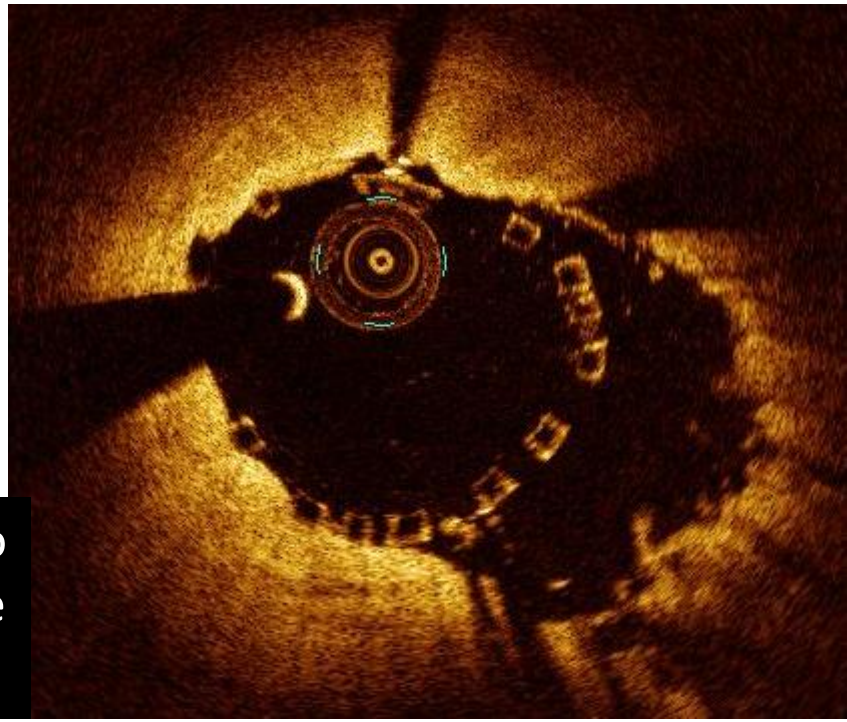

It is difficult to assess on 2D OCT still frames to what extend the MB stent struts are jailing the SB

And a final pullback was also performed to assess for distal edge dissections, apposition etc.

Final angio and discussion

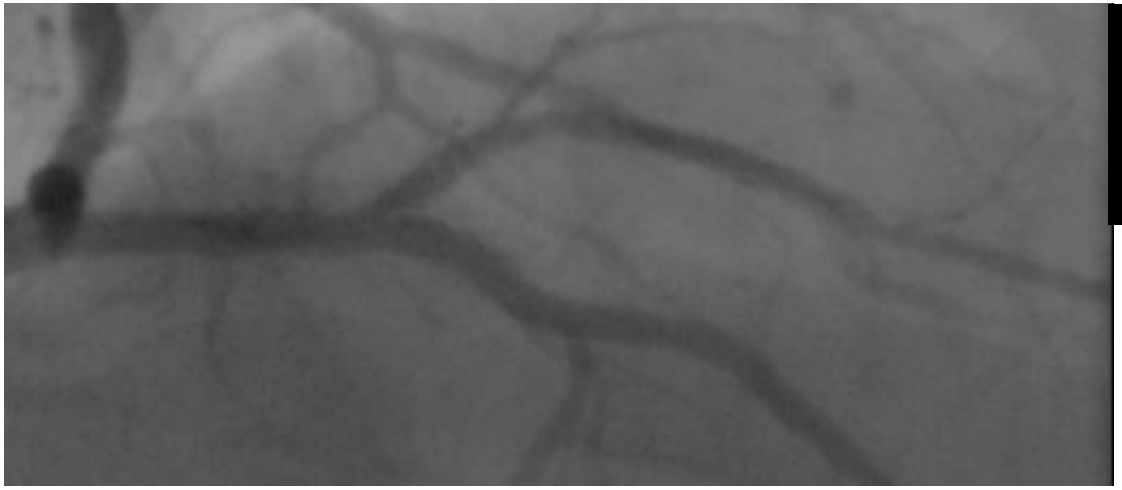

Final angio showed satisfactory results.

- Discussion:
  - Is it necessary/usefull to check wire position after rewiring the SB in the distal MB after Tryton placement?
  - Would it be usefull to know the ‘SB jailing pattern’ of the MB stent if angiographic result is satisfactory?

Discussion

- In-stent online 3D recontructions might help us with this

This example of an 3D-OCT recontruction of the first pullback (right after Tryton placem
patient shows how the MB is jailed (*), while it is clear that the SB wire is not.

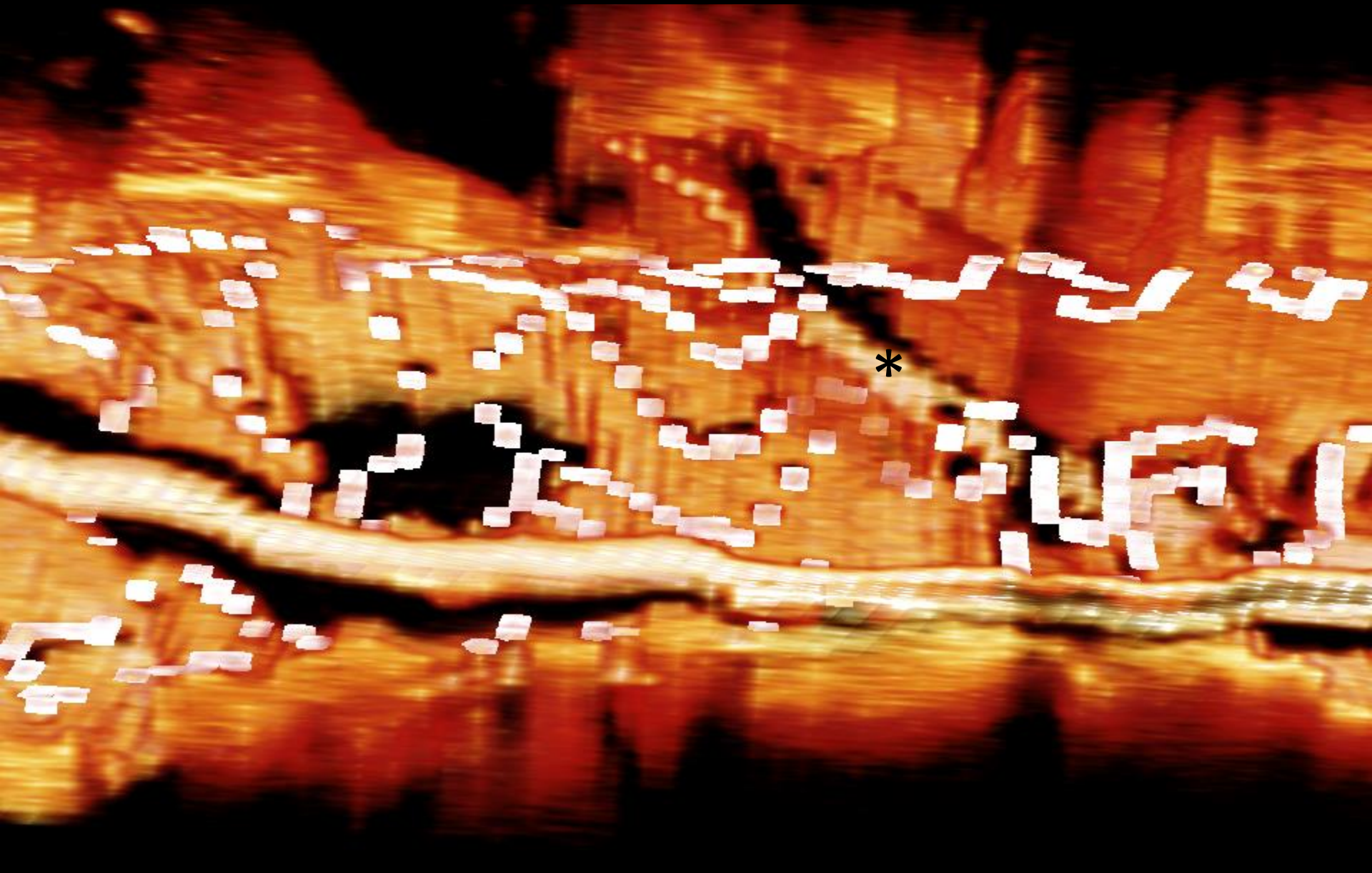

3D-OCT also allows for an assessment of the patterns of SB obstruction by the MB stent/scaffold struts. However, studies are needed to investigate the relationship between patterns of side branch jailing and clinical outcomes.