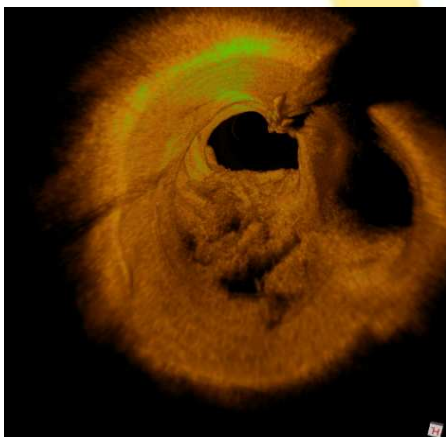

**Welcome to the 7th
European Bifurcation Club
14-15 October 2011 - LISBON**

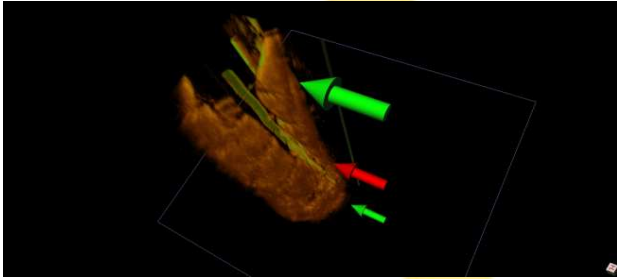
European Bifurcation Club



**Spatial perception of
bifurcation treatment aided by
3D OCT movie loops**

Niels R. Holm

niels.holm@ki.au.dk



Dr. Niels R. Holm

Disclosures:

- St. Jude Medical: research grant, speaker fees
- Terumo: speaker fee
- Medis medical imaging: research collaboration

European Bifurcation Club



PCI Research

Aarhus University Hospital, Skejby • Denmark niels.holm@ki.au.dk

niels.holm@ki.au.dk

Aarhus University Hospital
SKEJBY 



3D OCT movie loops: background

- 3D OCT still images are highly informative and movie loops might increase the spatial perception
- Movie loops are practical in the non-technician clinical situation



On-line 3D OCT rendering

- Medis prototype
 - 3D QCA to OCT/IVUS co-registration*
 - In-lab application
 - High res. 3D OCT movie loops, 7 fps
- St. Jude C7 FD-OCT
 - 20 mm/s, 100 fps, 1024x1024
 - Network connected

* Fusion of 3D QCA and IVUS/OCT; Tu et al; International Journal of Cardiovascular Imaging, 2011



On-line 3D OCT co-registration

QAngioXA 3D - Straight (prototype version, not for clinical decision making)

File View Analysis

2D frontal projection 3D view 2D Lateral projection

RAO 29, CRAN 6
DS 67%, 24.7 mm
Pro 3.5 mm, 3.2 mm
Dis 2.8 mm, 2.4 mm
Bending Angle: 163

Segment analysis results (mm)

3D len.	Vol.	Frontal len	Lateral len
24.69	93.93	22.77	19.88

MLD	Ref. diam	Diam Obs	Area Obs
0.93	2.82	67.0%	85.9%

Diam: Pro 3.30 Dis 2.56
Area: Pro 8.57 Dis 5.14

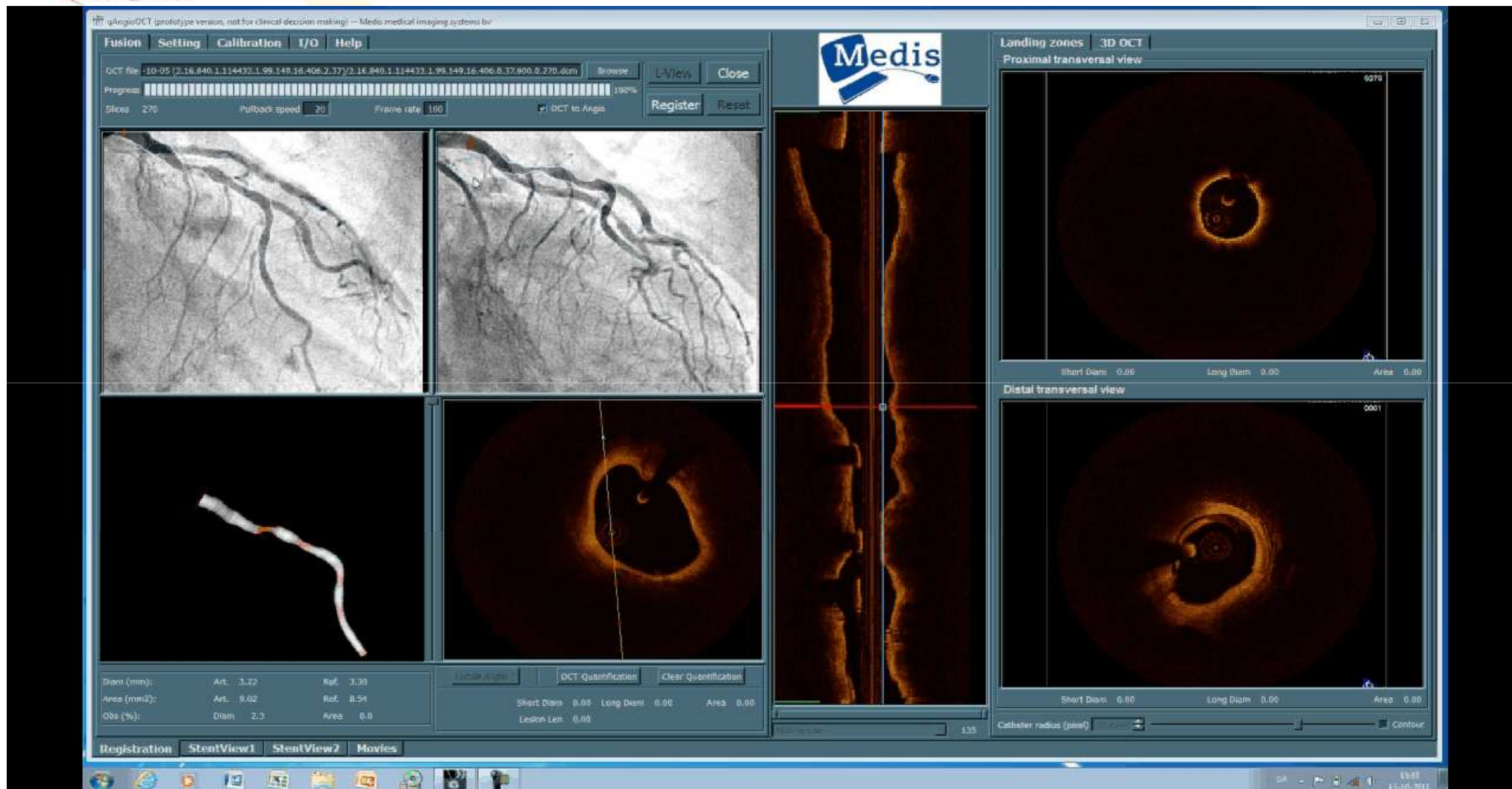
MLD approach
 Relative MLD Absolute MLD

3D view style
 Angiographic view Mirror view

Pixel Spacing is 0.258, SID is 1156, SAID is 765
Current Selected Image: RAO 33.5, CAUD 24.7
Pixel Spacing is 0.258, SID is 1119, SAID is 765
AAD between the 2 angiographic views is : 36.4
Frontal projection angle: RAO 33.3, CRAN 11.7
Lateral projection angle: RAO 33.5, CAUD 24.7
Frontal image contours have not been detected



On-line 3D OCT rendering



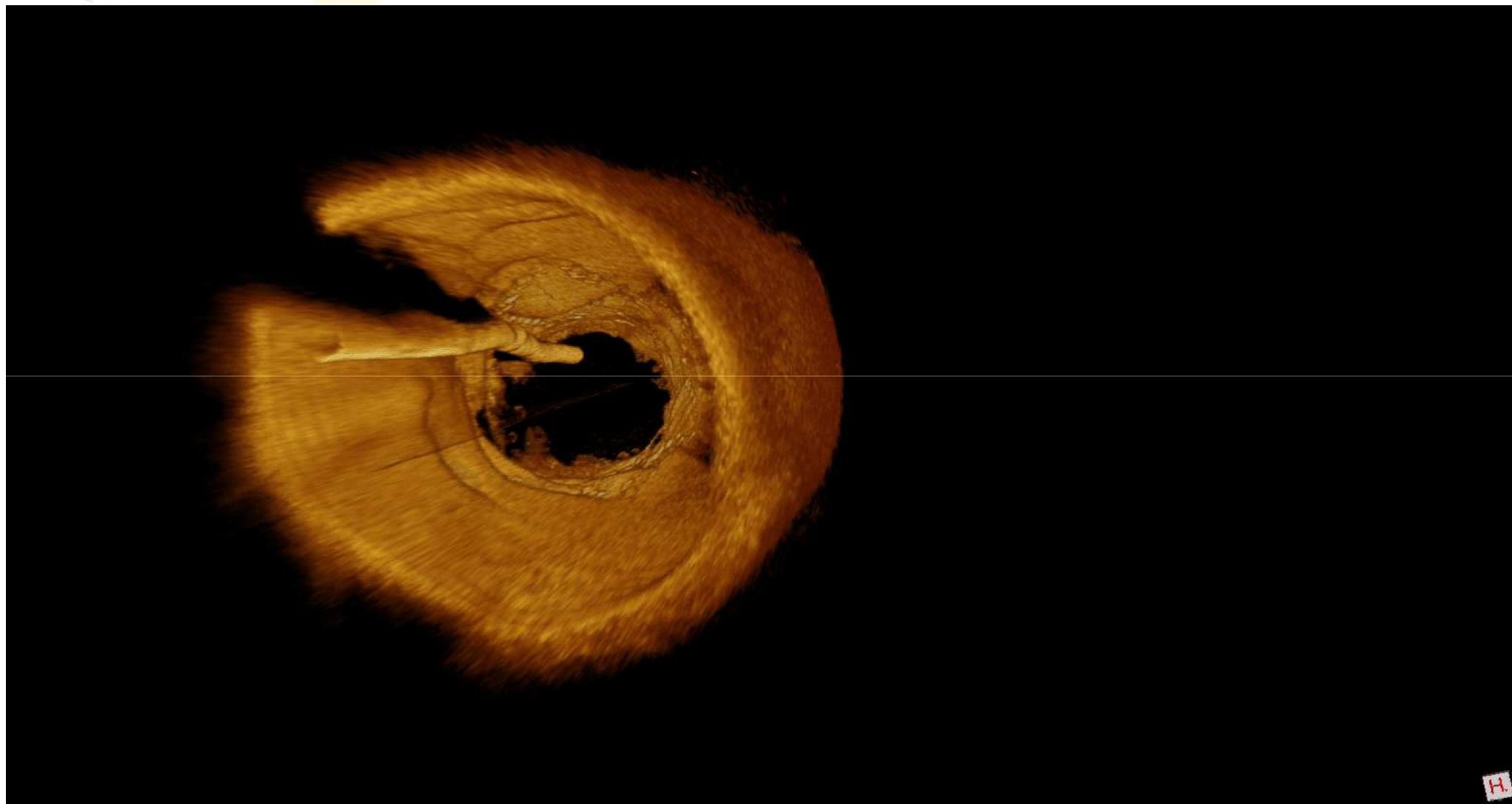


3D OCT: applications

- Lesion
 - Procedural stepwise assessment
 - Post PCI
 - Follow-up
 - Event
-
- No “Photoshop” processing used!

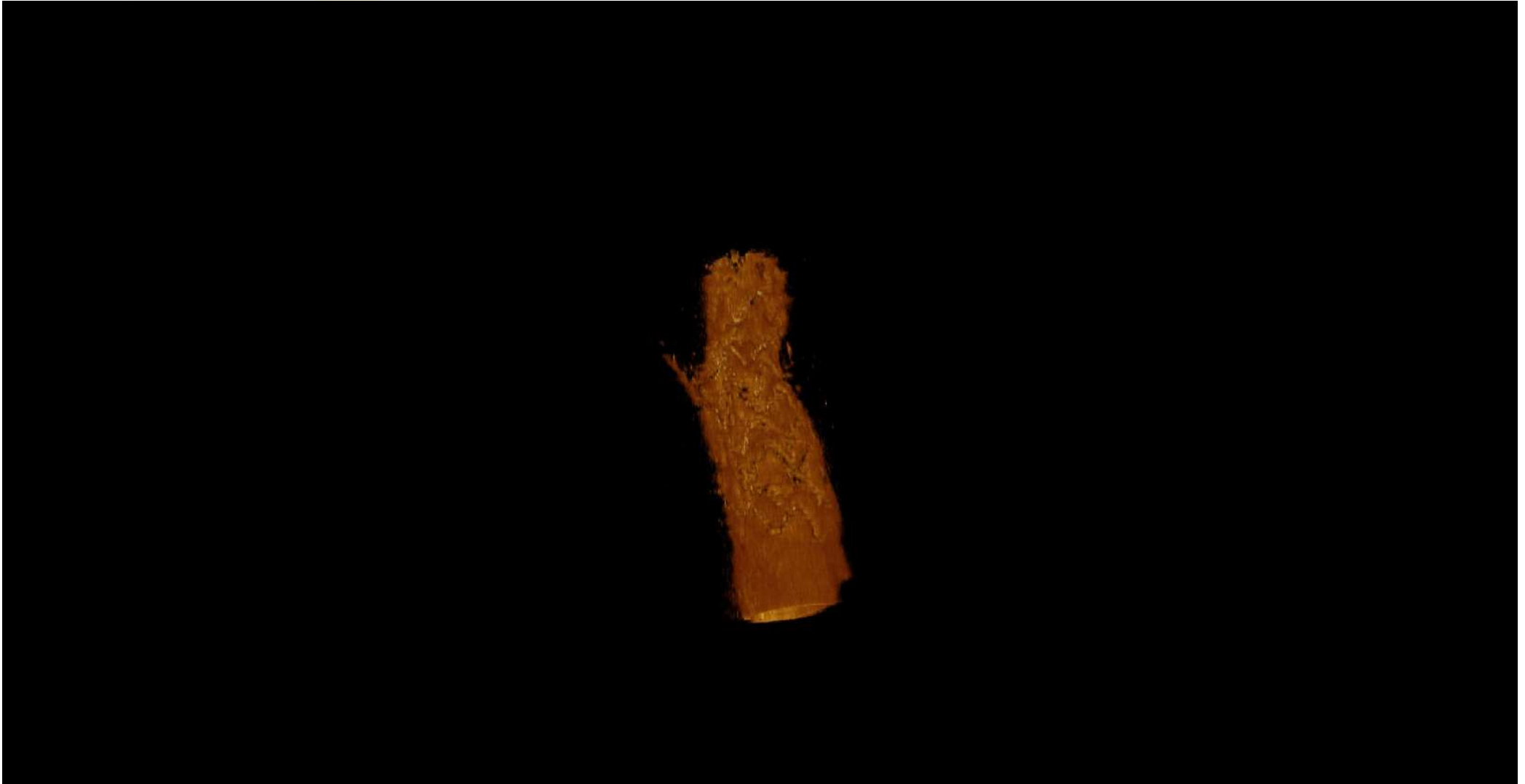


3D OCT: Overhanging struts



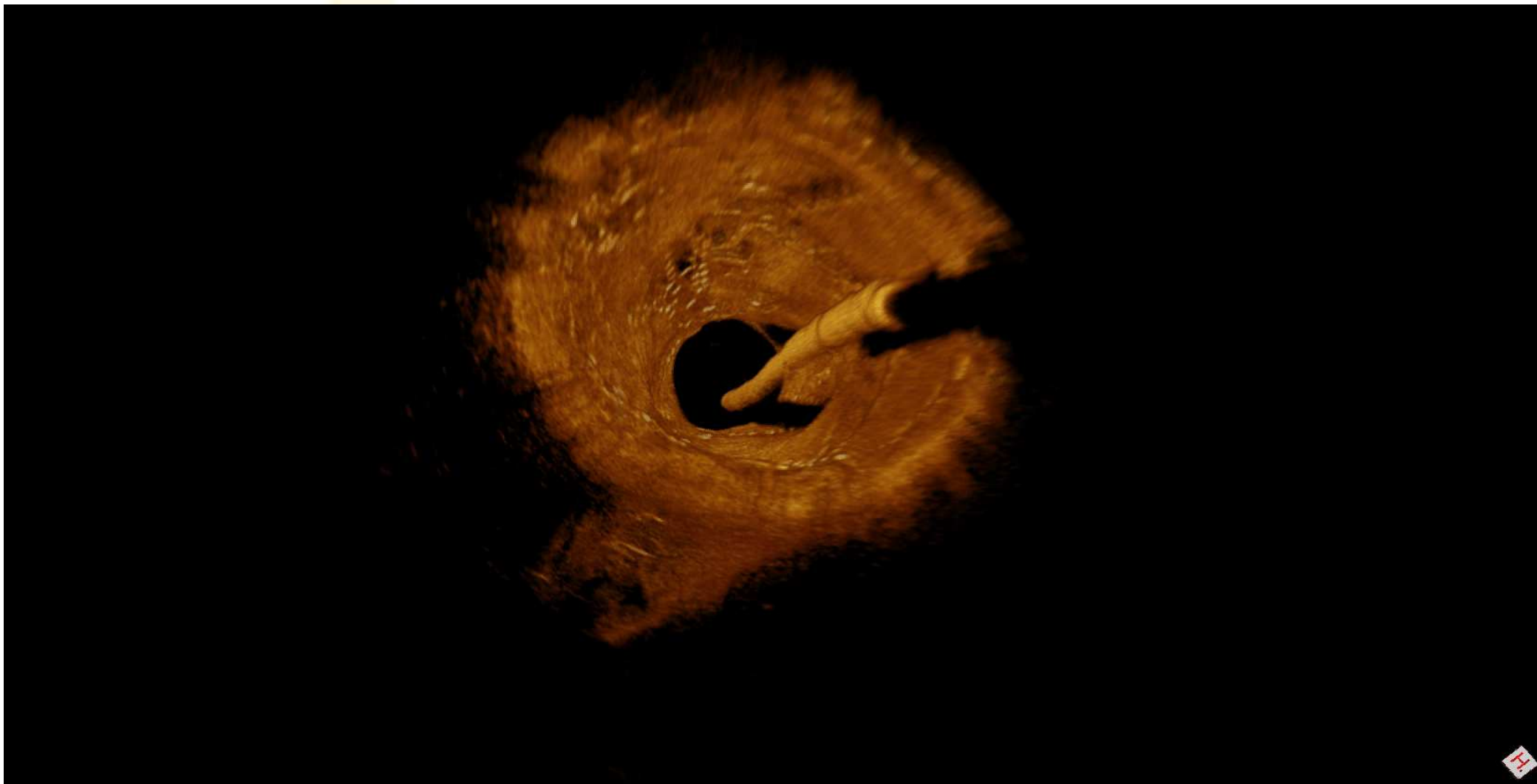


3D OCT: Culotte SB first (post-PCI)



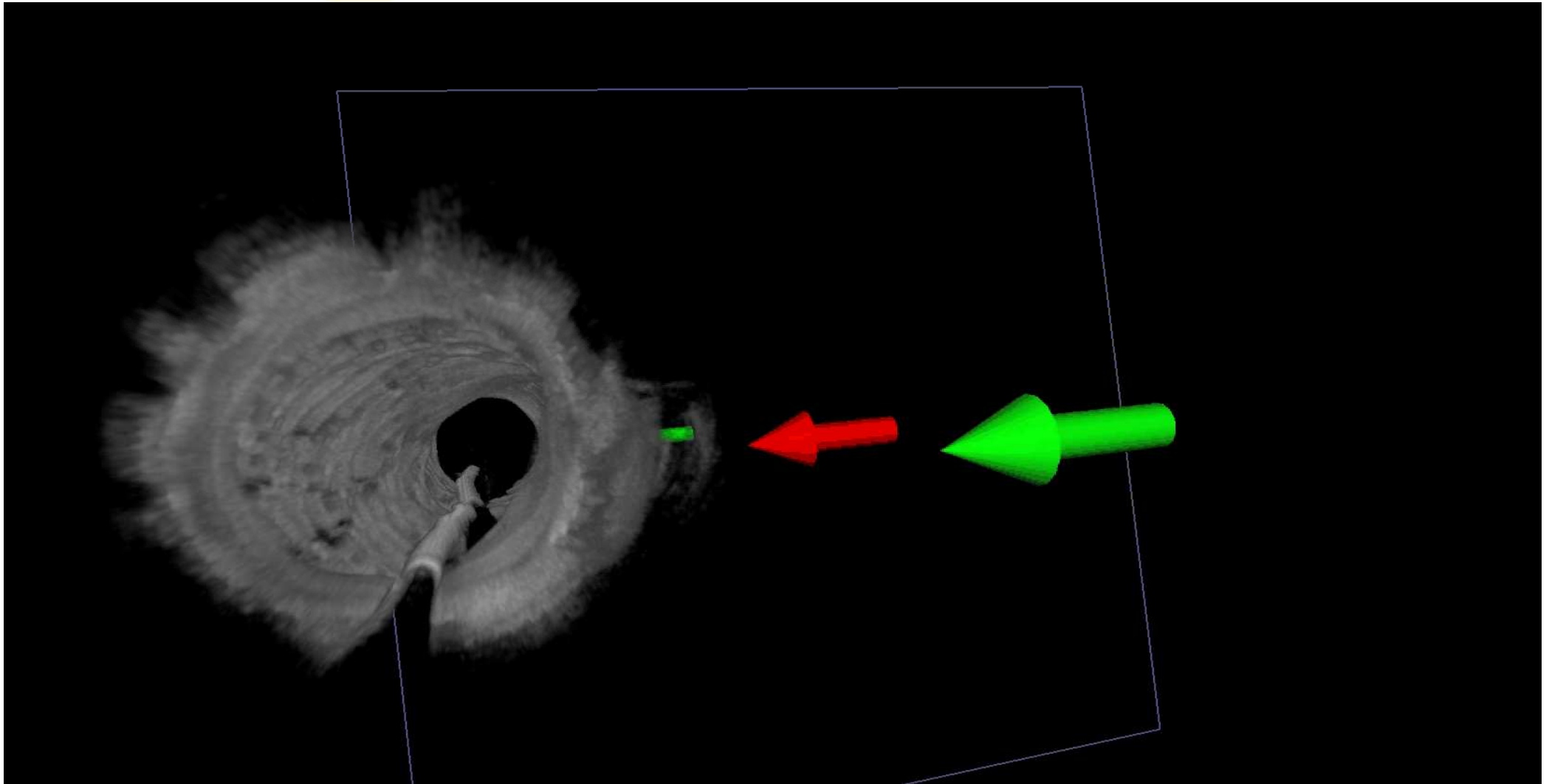


3D OCT: Culotte (8m follow-up)






3D OCT: Jailed SB follow-up



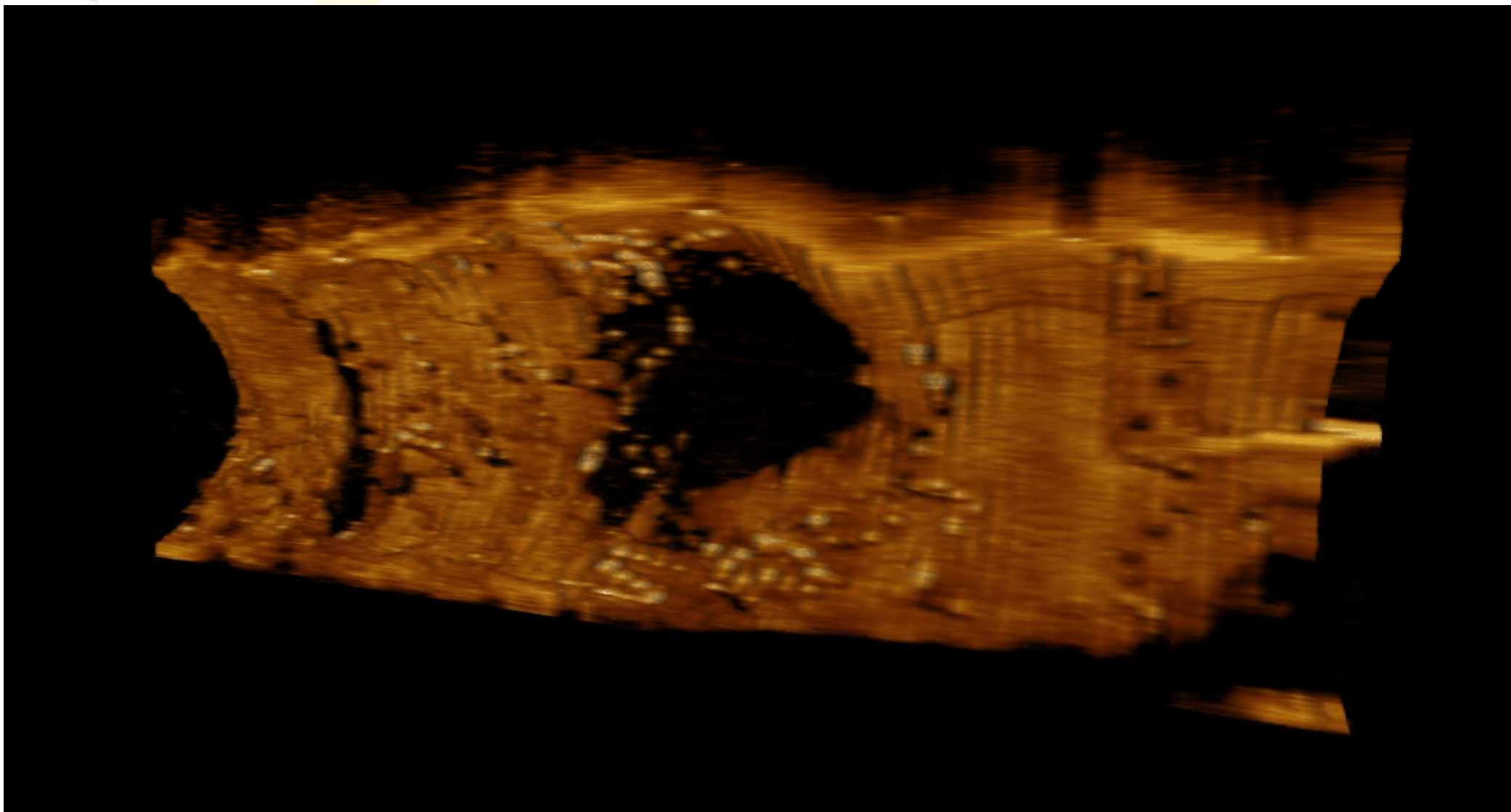


3D OCT: Cul. SB first. Wirer position



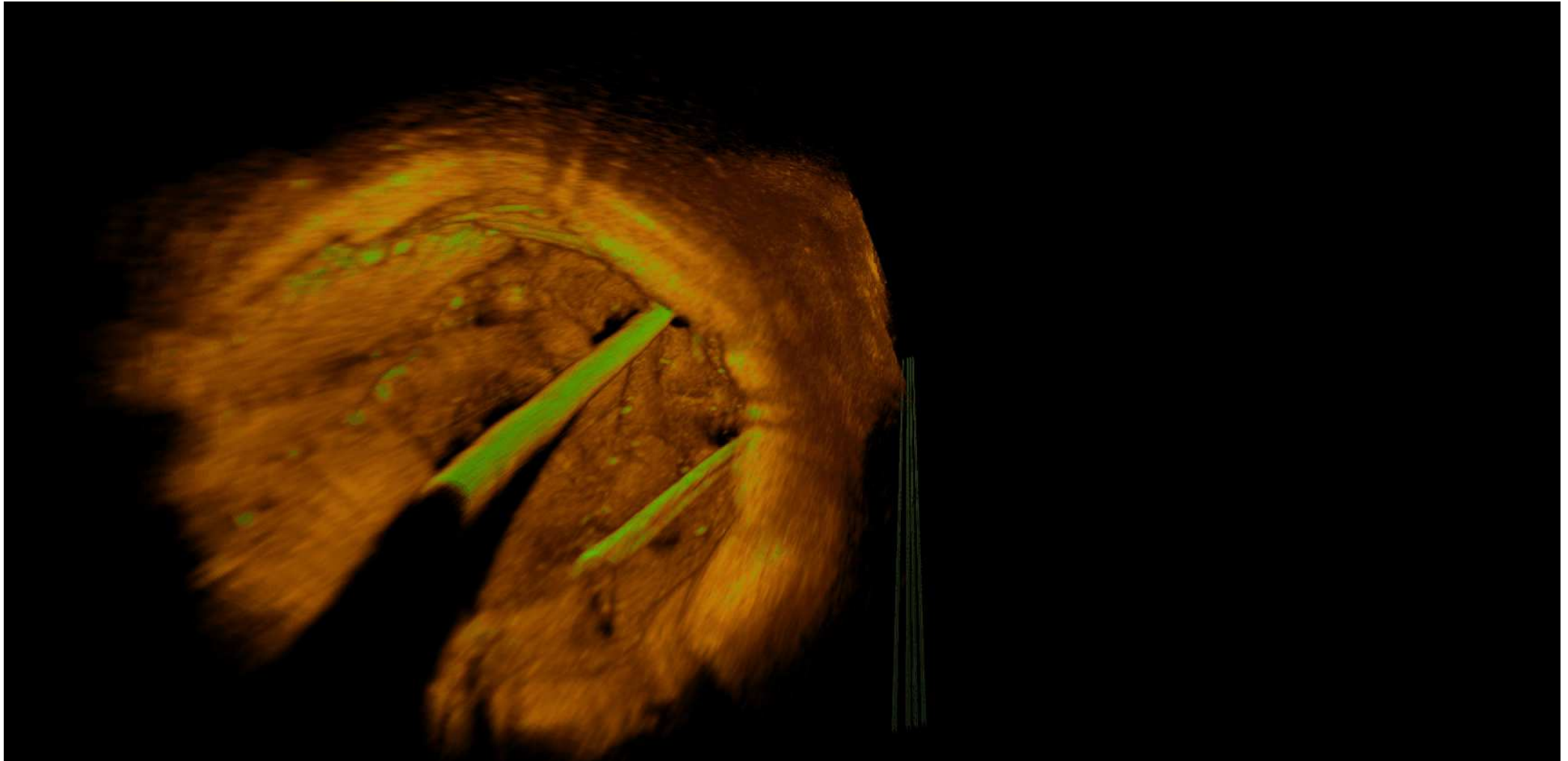


3D OCT: Result prox. wire position



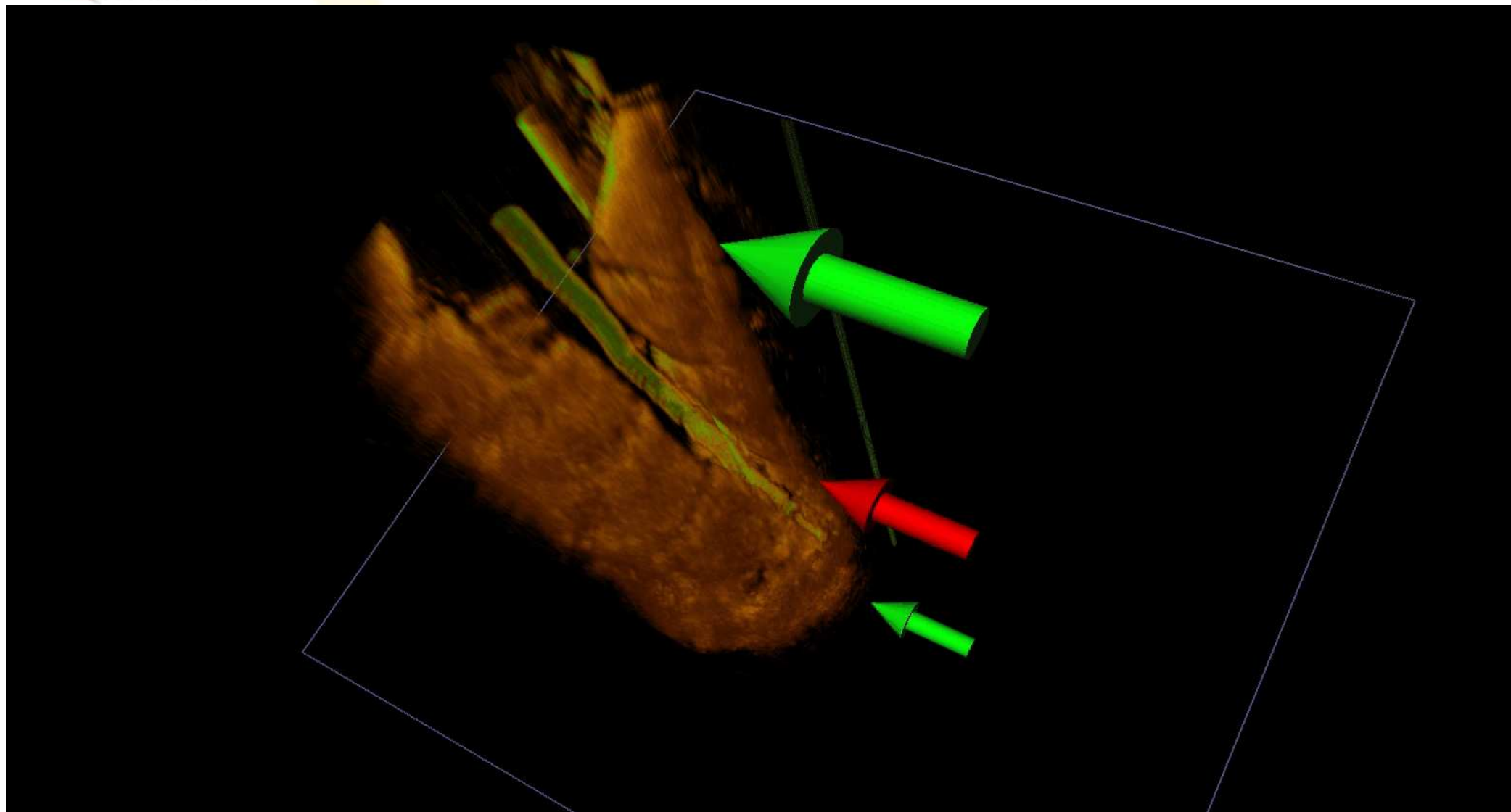


3D OCT: Wirer position ?



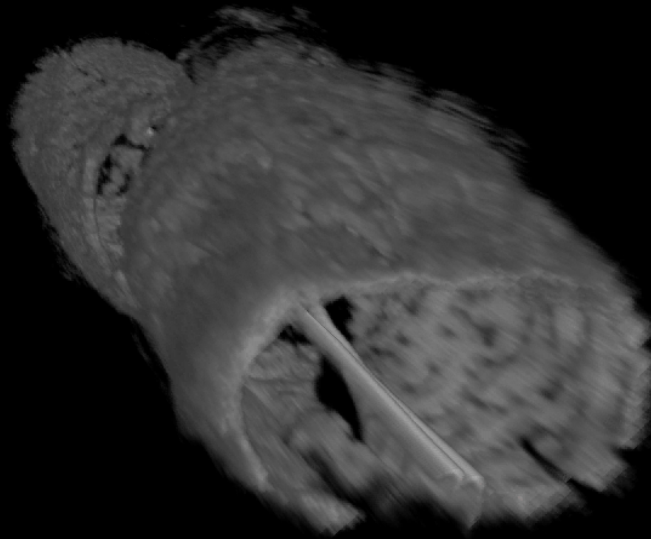


3D OCT: Wirer position ? - result





3D OCT: Prox. distortion after POT





3D OCT: VL Stent thrombosis

3 yrs after:

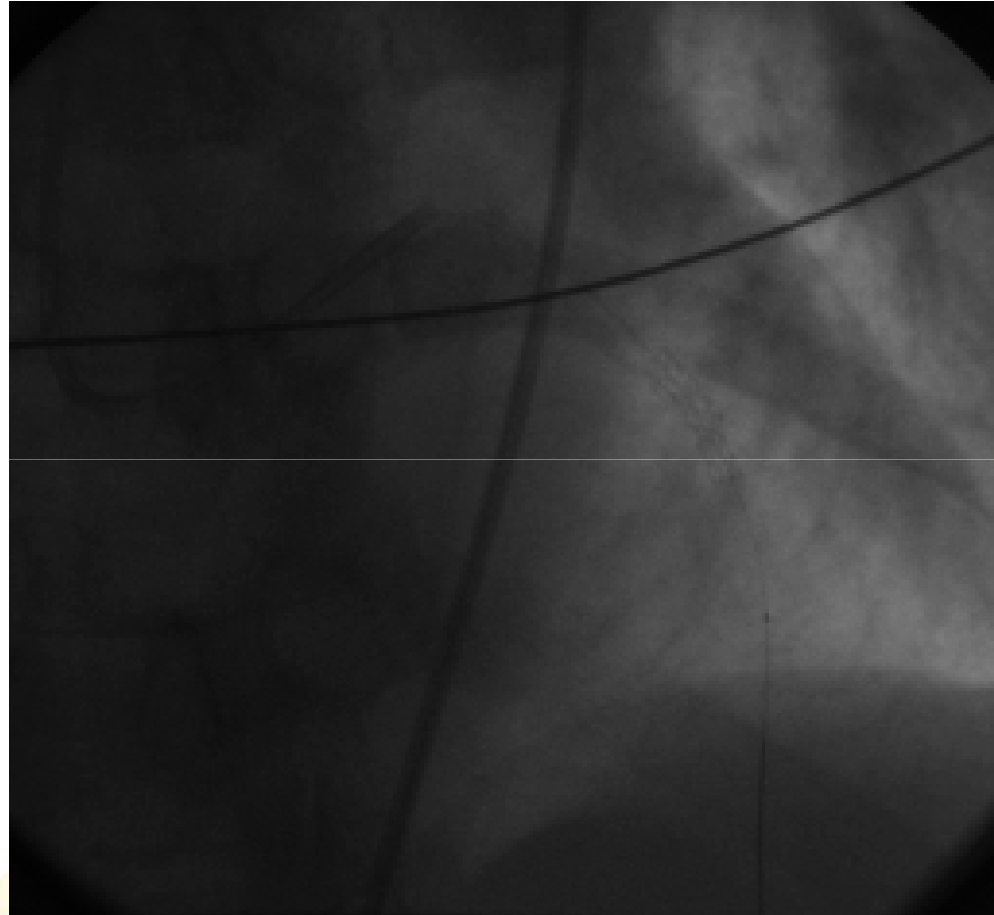
LAD/D2

Simple technique

Cypher stent

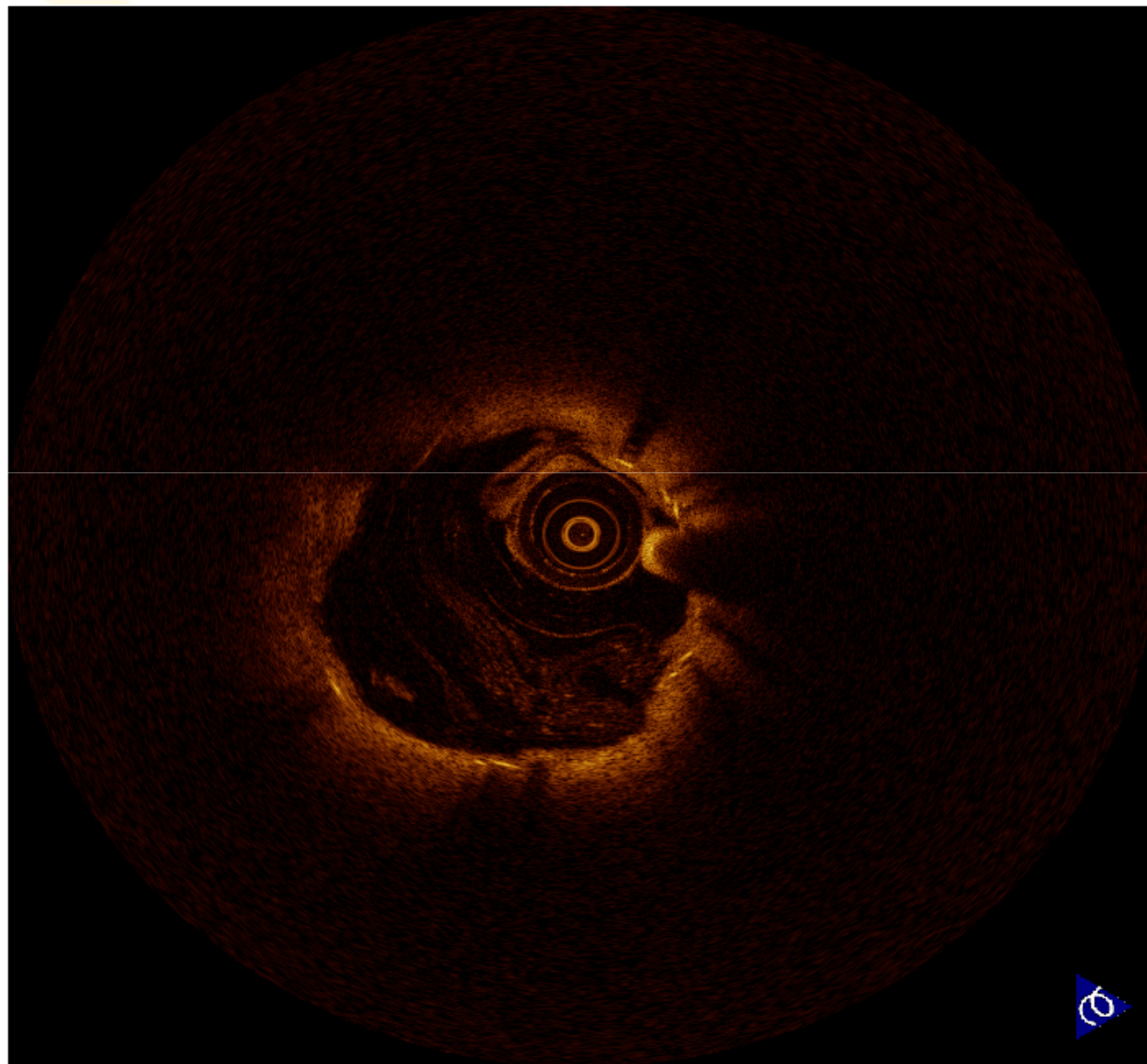
Kissing

Index angio: OK



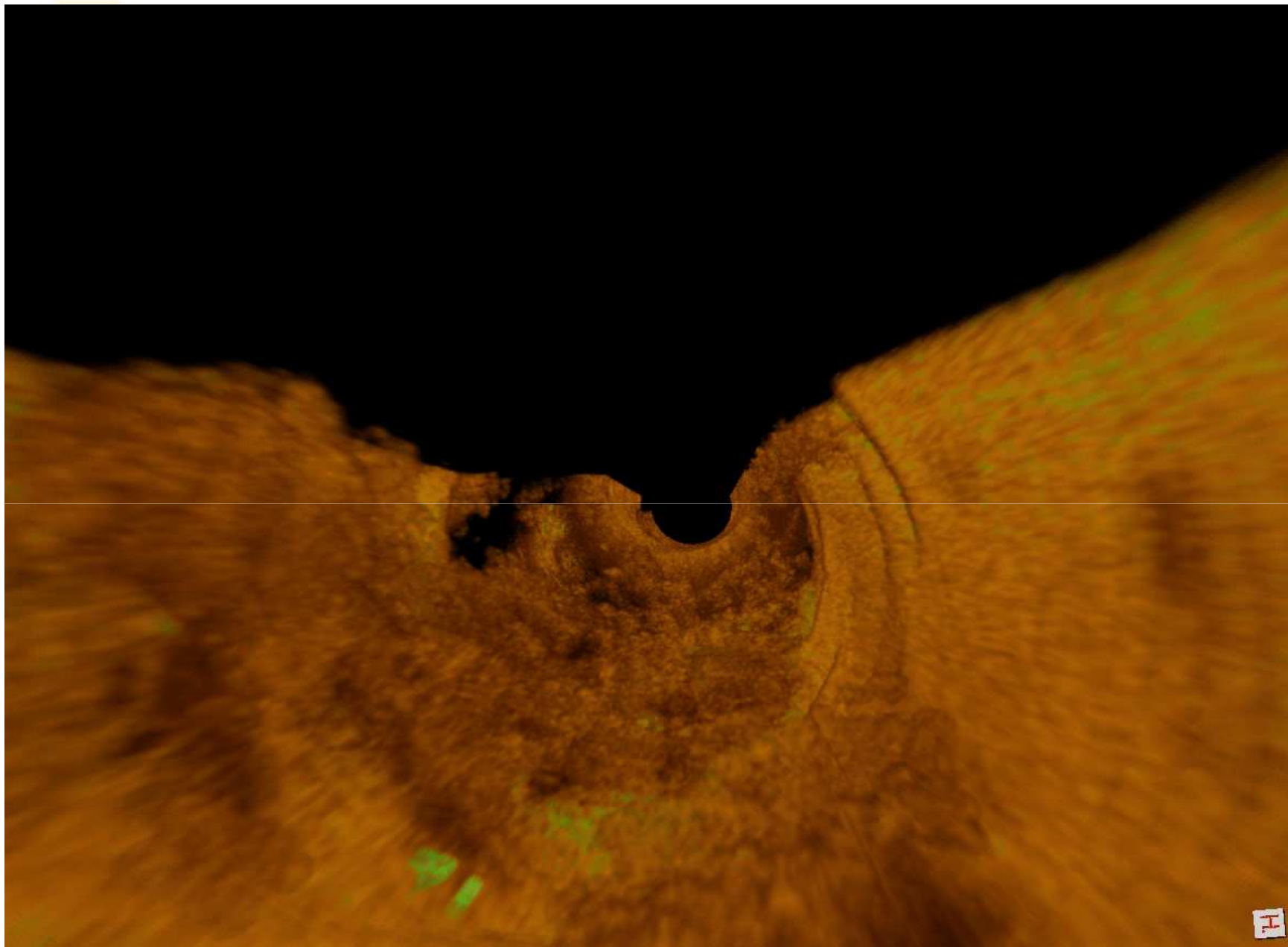


3D OCT: VL Stent thrombosis



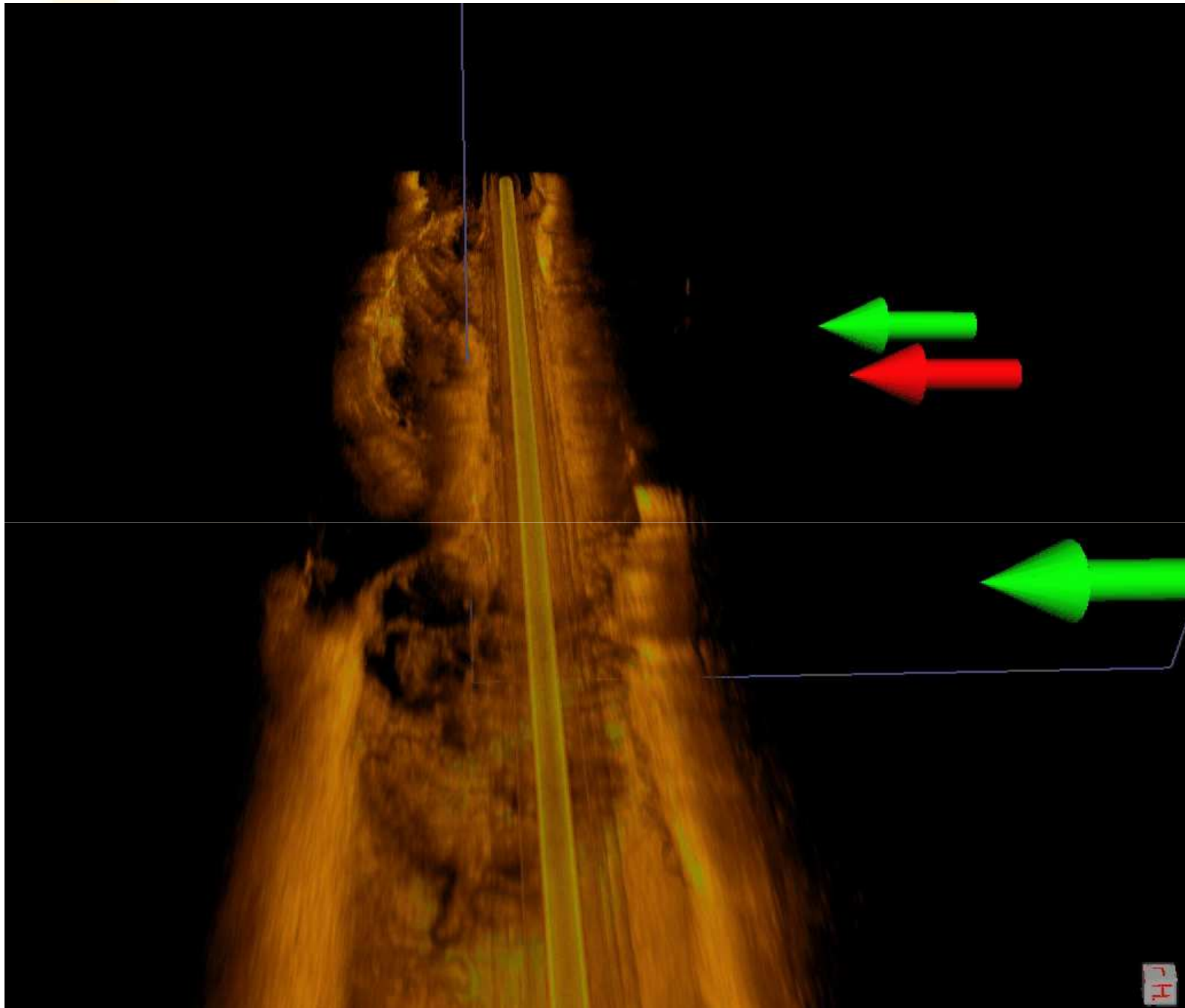
PCI Research

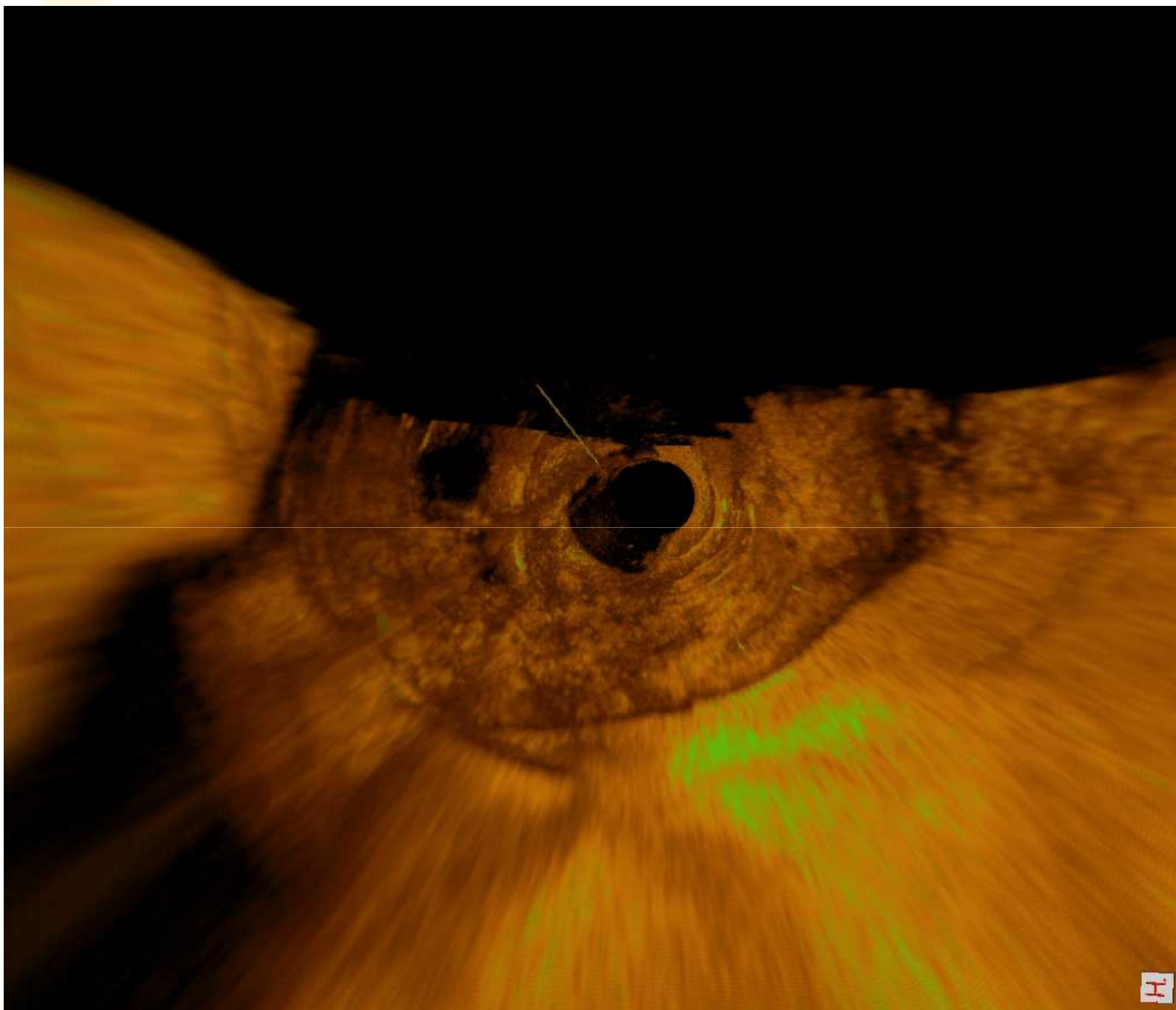
Aarhus University Hospital, Skejby • Denmark niels.holm@ki.au.dk



PCI Research

Aarhus University Hospital, Skejby • Denmark niels.holm@ki.au.dk





PCI Research

Aarhus University Hospital, Skejby • Denmark niels.holm@ki.au.dk


Aarhus University Hospital
SKEJBY





3D OCT: Conclusion

- Co-registered 3D OCT rendering can be performed on-line
- 3D OCT movie loops may aid spatial perception of bifurcation treatment and difficult cases



3D OCT: Acknowledgements

Aarhus University Hospital,
Skejby, Denmark

Jens Flensted Lassen
Leif Thuesen
Michael Maeng
Evald Hoej Christiansen

Leiden University Medical Center
Medis medical Imaging

Shengxian Tu
Gerhard Koning
Johan H.C. Reiber

Thank you

niels.holm@ki.au.dk