

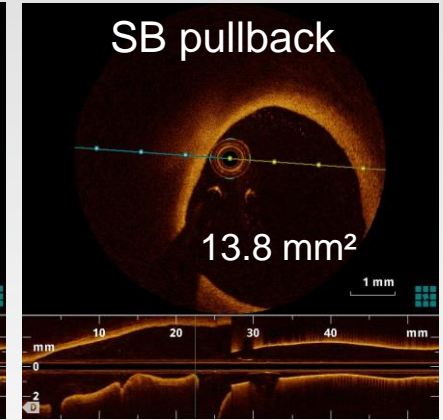
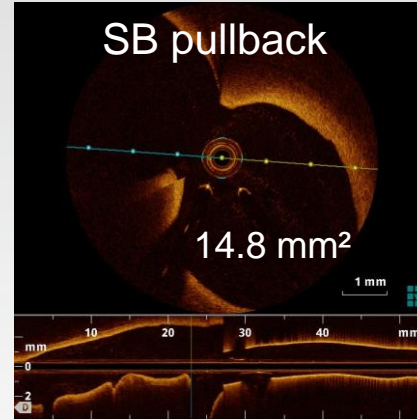
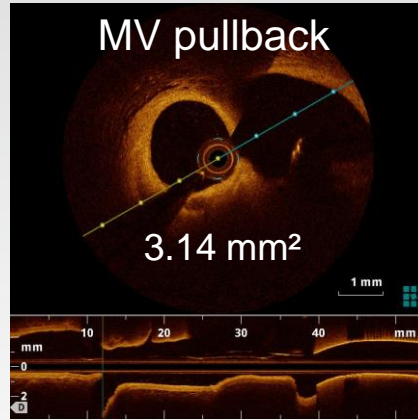
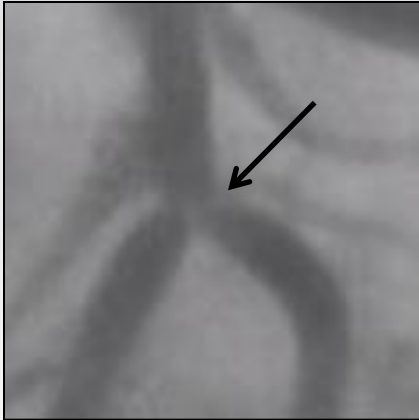


# The Side-branch OCT Pullback Show off or show troubles?

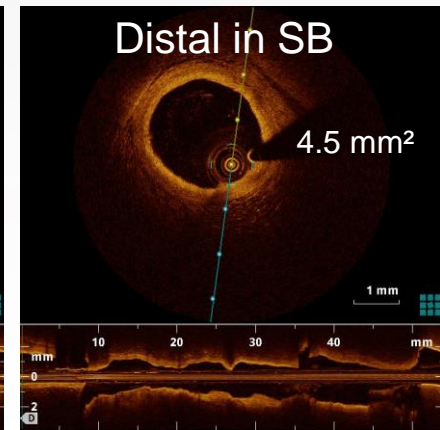
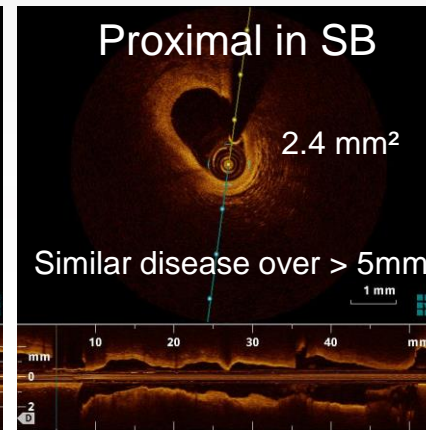
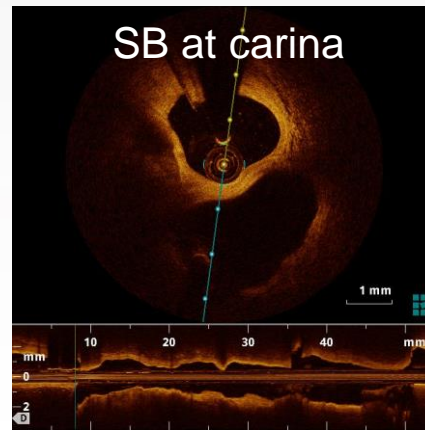
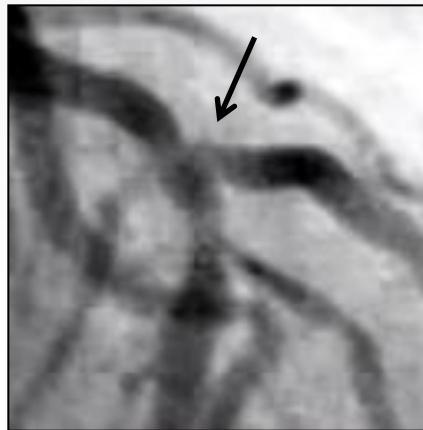Christophe Dubois, MD, PhD, FESC  
University Hospital Leuven, Belgium

# OCT in the SB pre-PCI

## Evaluation of dubious lesions



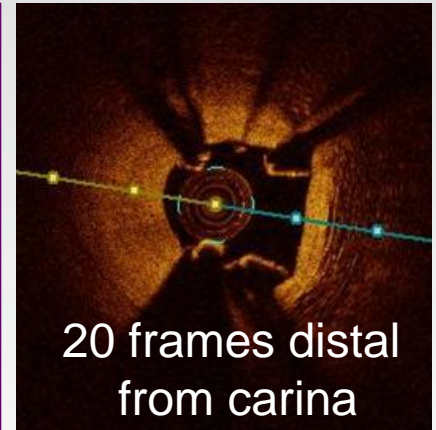

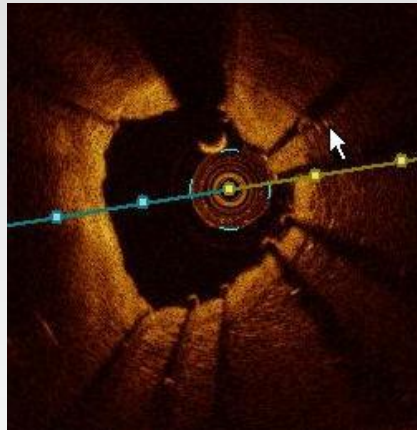
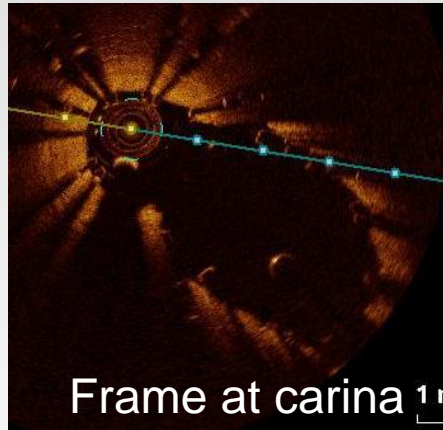
Side-branch involvement: yes or no?



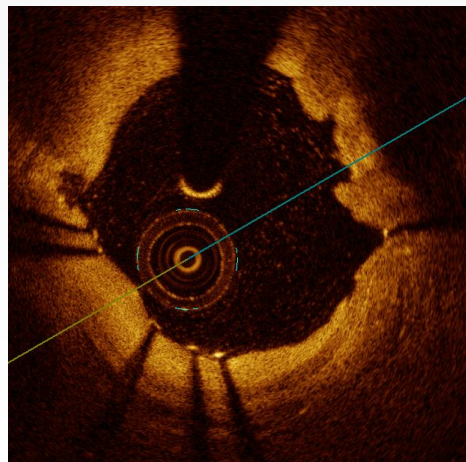
Extent of SB disease ?

# OCT in the SB during PCI

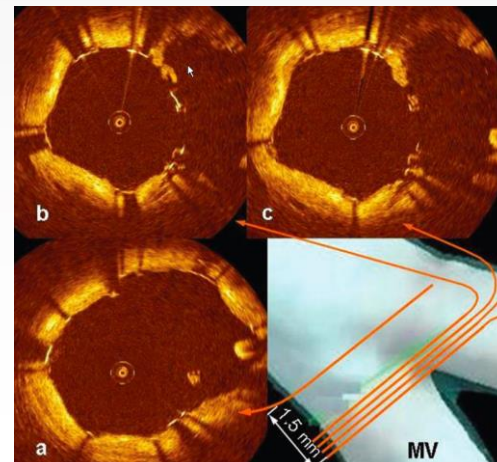
Documentation of technical success/failure



AXXESS technology with struts engaged deeply in the SB, sparing carina



XIENCE SBA from SB

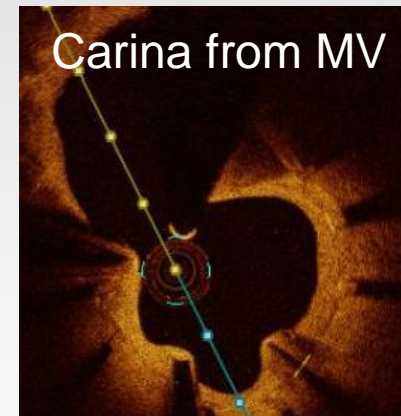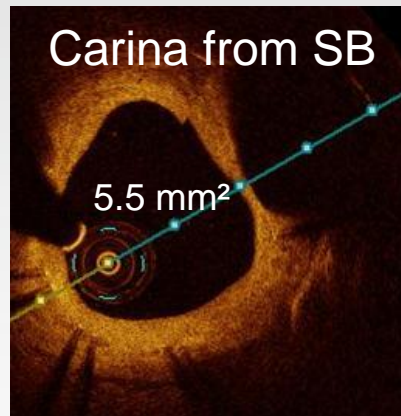
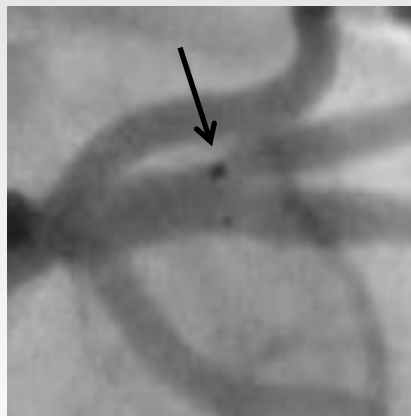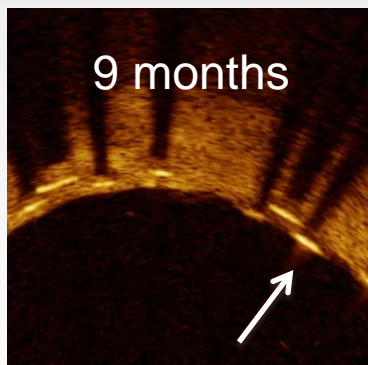
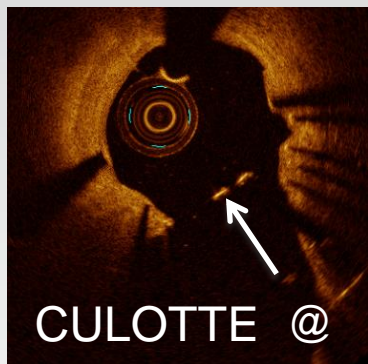


Neocarina with Culotte/Tryton

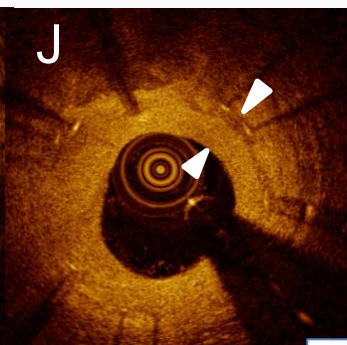
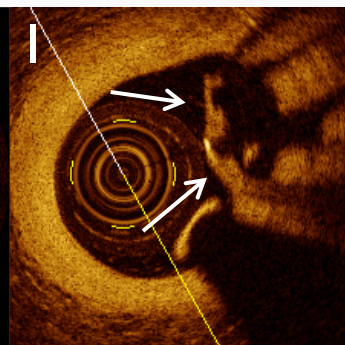
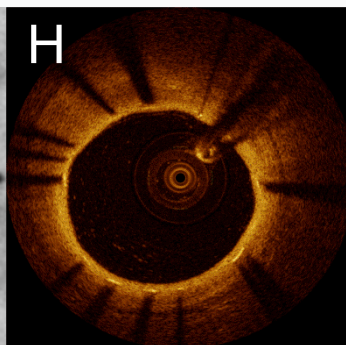
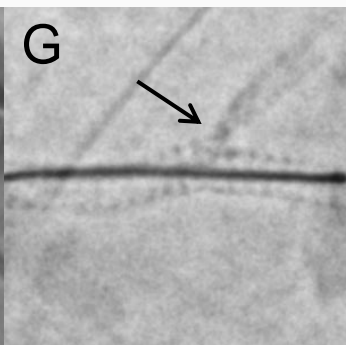
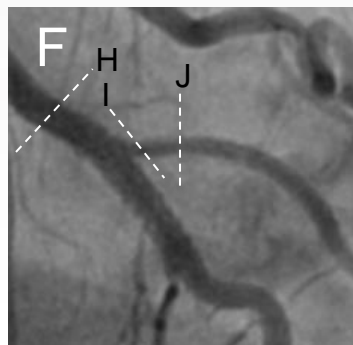


# OCT in the SB at FU

## Healing and failure



AXCESS at 9 months ostial SB restenosis?



TRYTON at 9 months: Dubois, Adriaenssens, Ughi et al. CCI 2013 Feb;81(3):E155-64