Left Main Treatment

with Crush

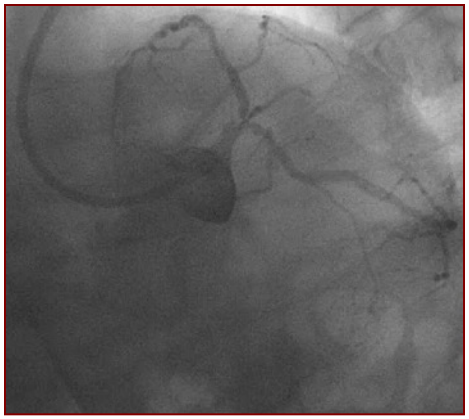

OPEN ISSUES

- **Distal left main bifurcation lesion**
  - Challenge for the interventional cardiologist
  - Procedure technically demanding
  - Can finish with a poor result
  - Correct treatment requires
    - adequate strategy
    - *tailored* approach

Tailored approach: One or Two Stents ?

- **One stent**
  - if lesion involves only one vessel
  - if moderate lesion on branch vessel

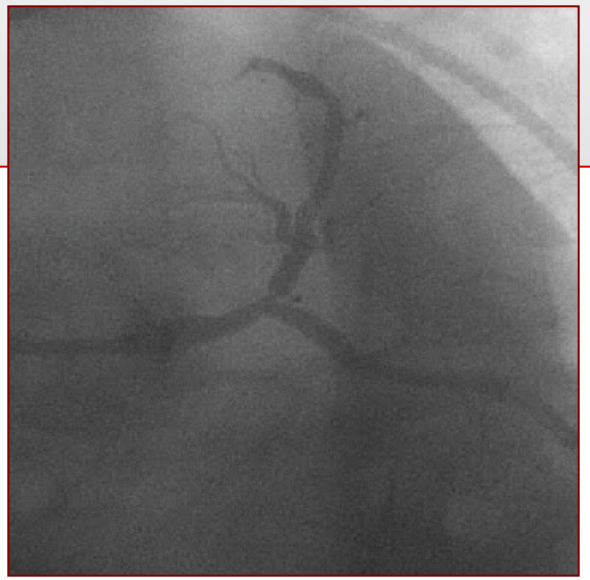

Tailored approach: One or Two Stents ?

- **Two stents**
  - if severe lesion on both
  - if significant lesion and/or dissection post branch dilatation

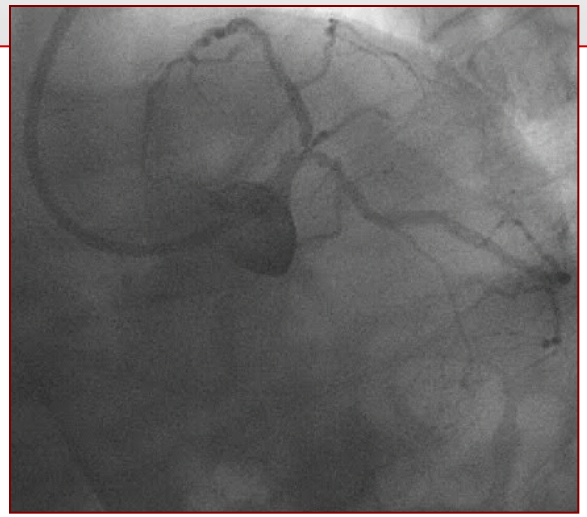

Tailored approach: Two stents

Crush

- LAD and Cx involvement
- Adequate anatomy

Theoretical advantages of the crushing technique

1. Predictable procedure
2. Continuous control of both vessels
3. No alteration of haemodynamic status
4. No need in general for circulatory support

Theoretical Drawbacks of crushing technique

1. Excesive metal
2. Risk of thrombosis
3. Risk of

Left main PCI

After Crush

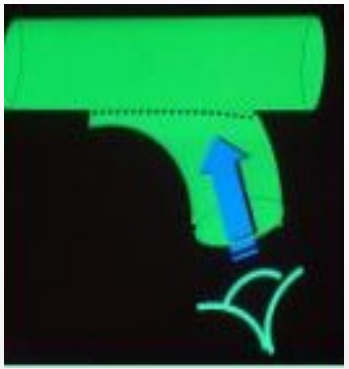

After Kissing

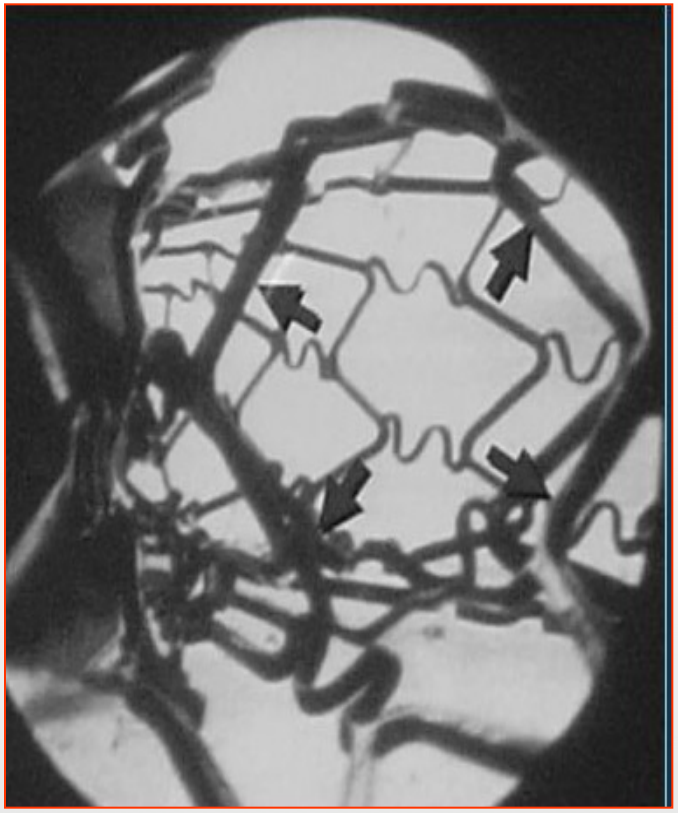

Step By Step Description

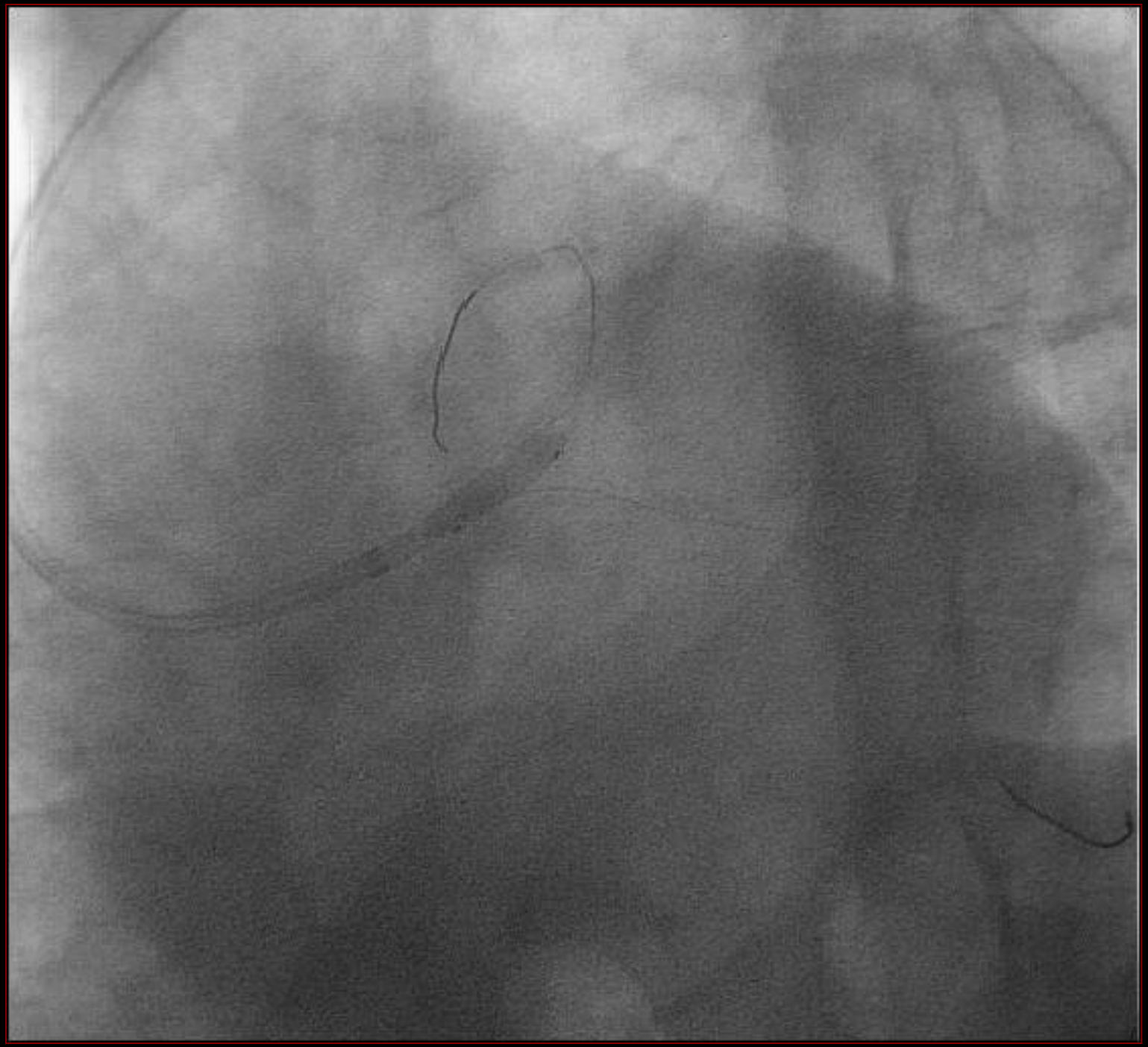

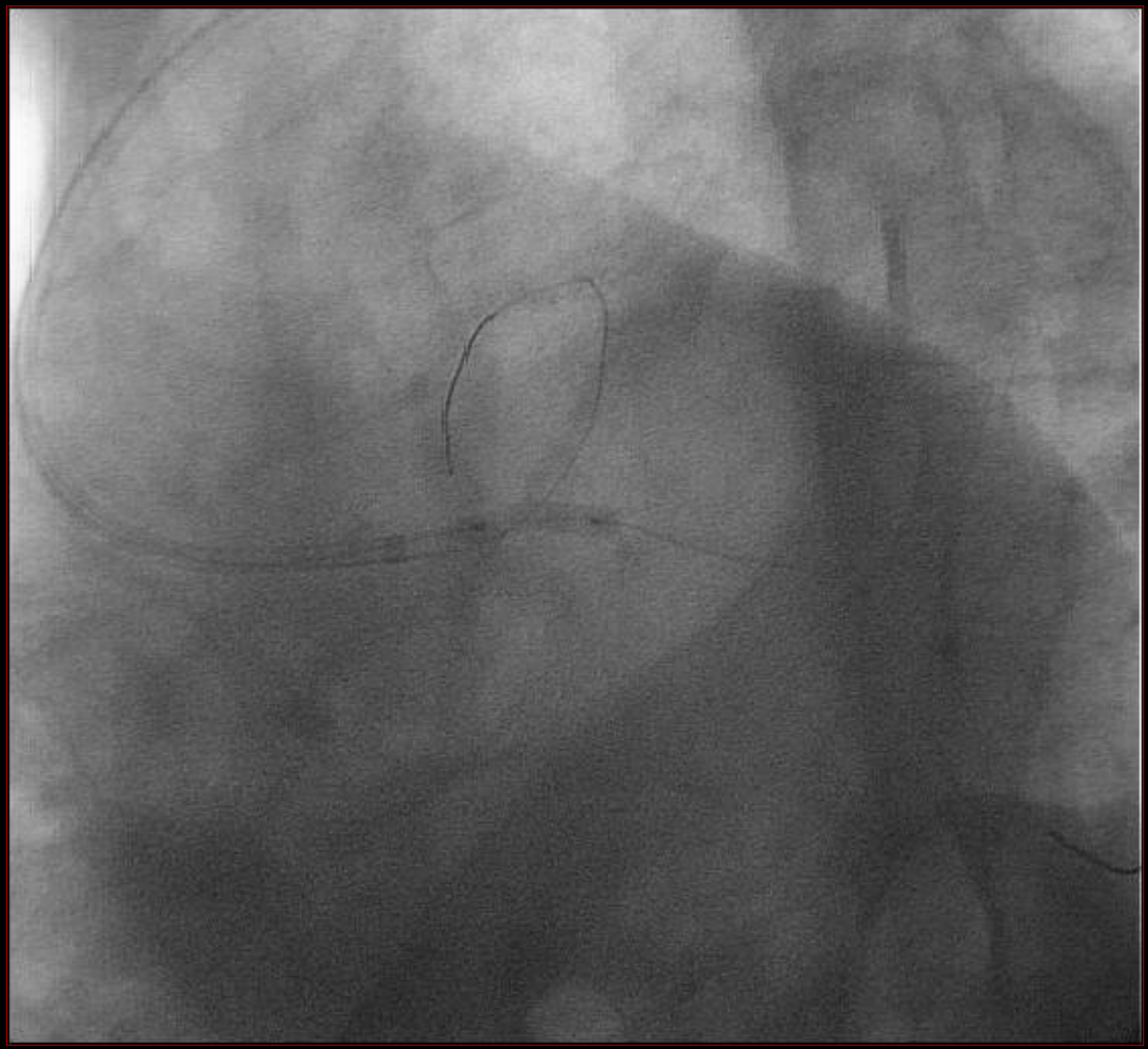

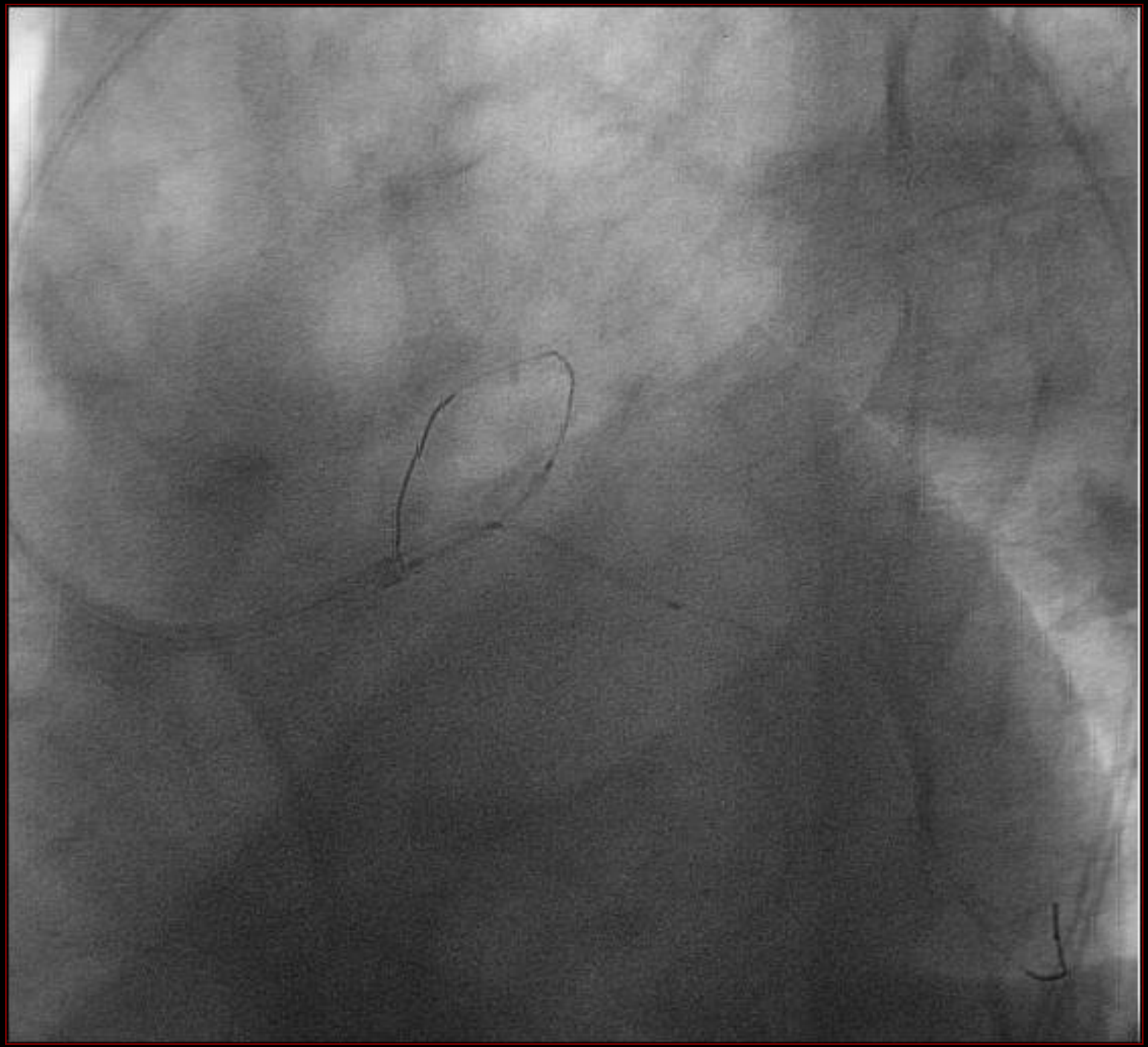

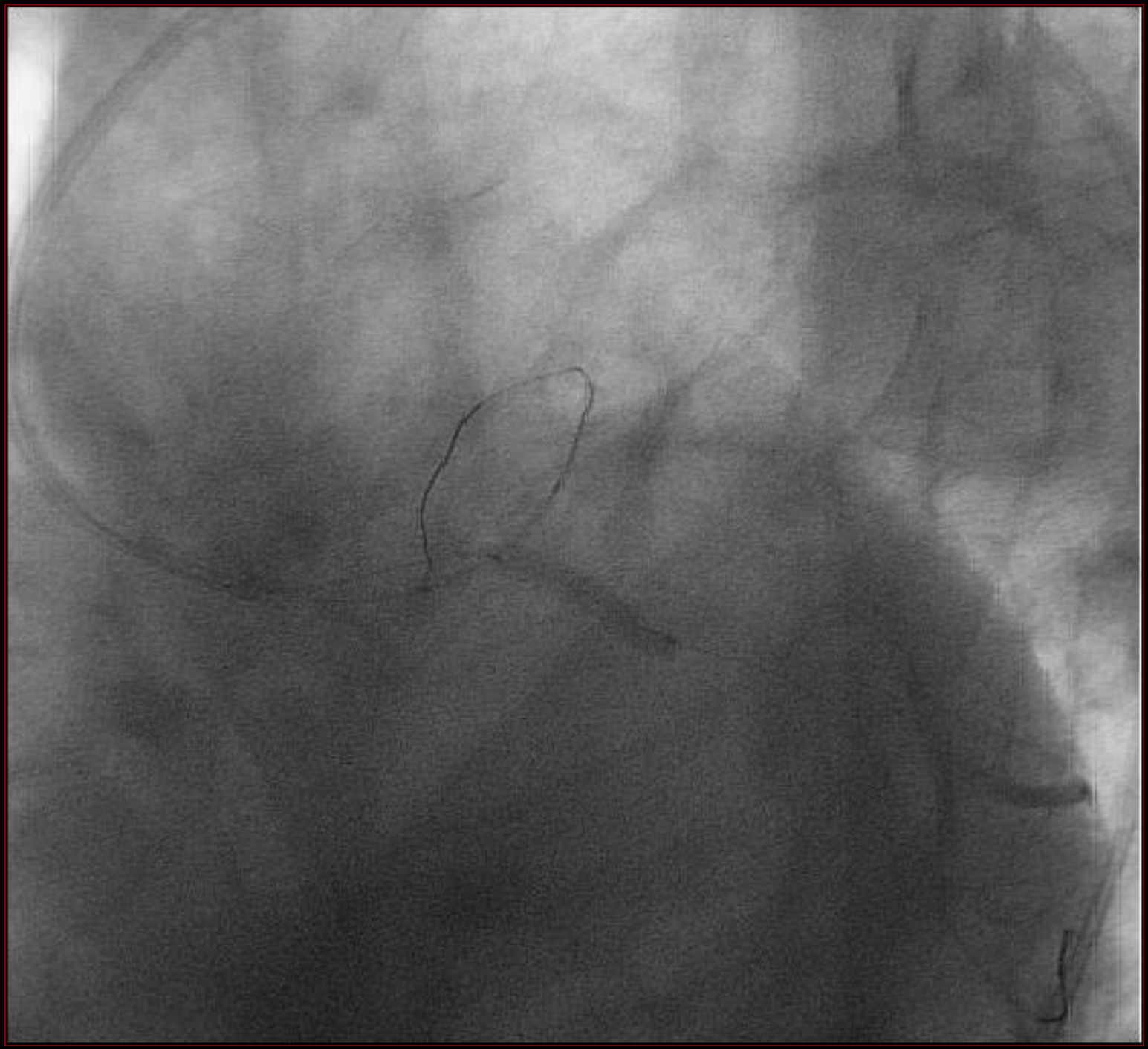

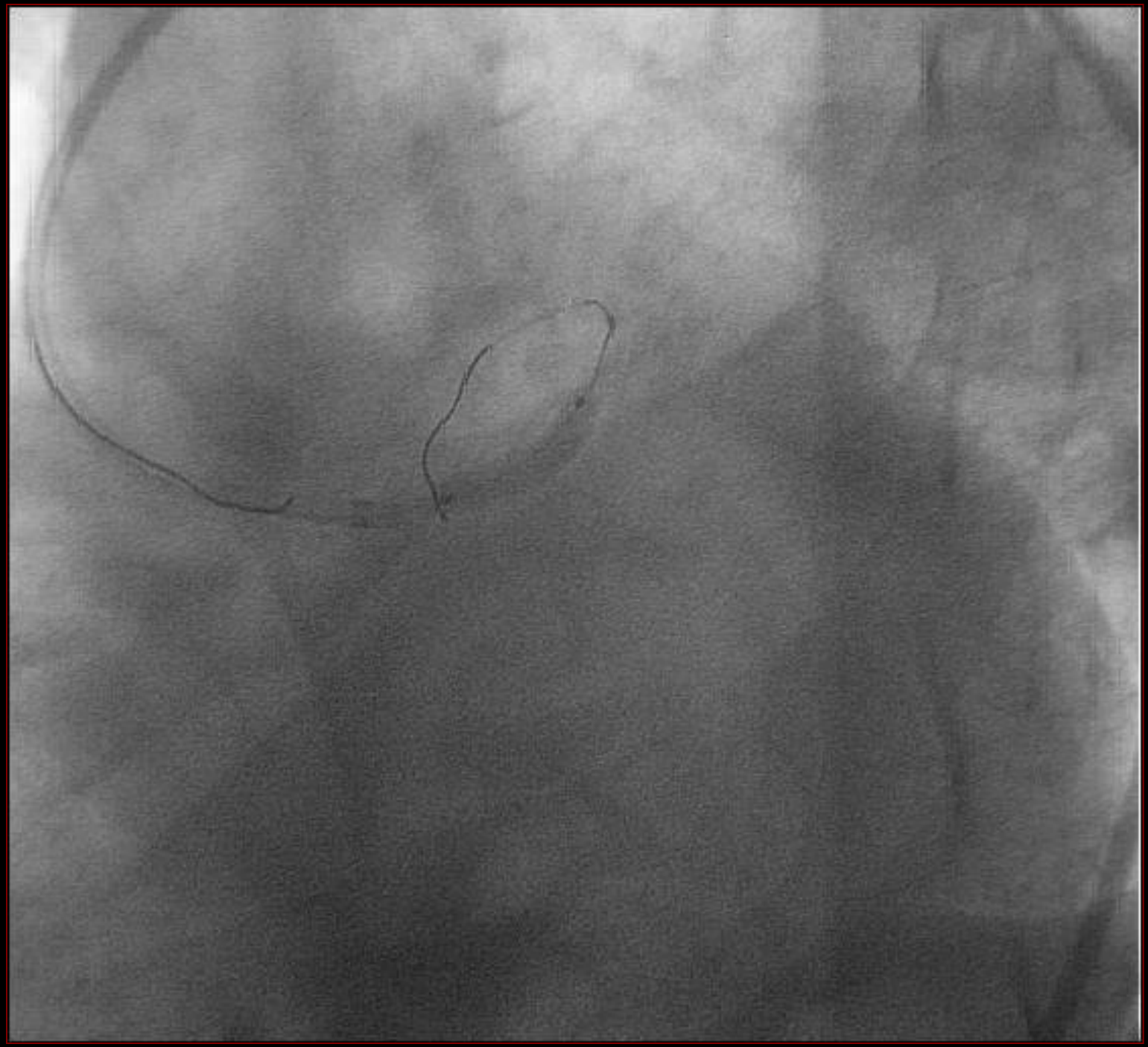

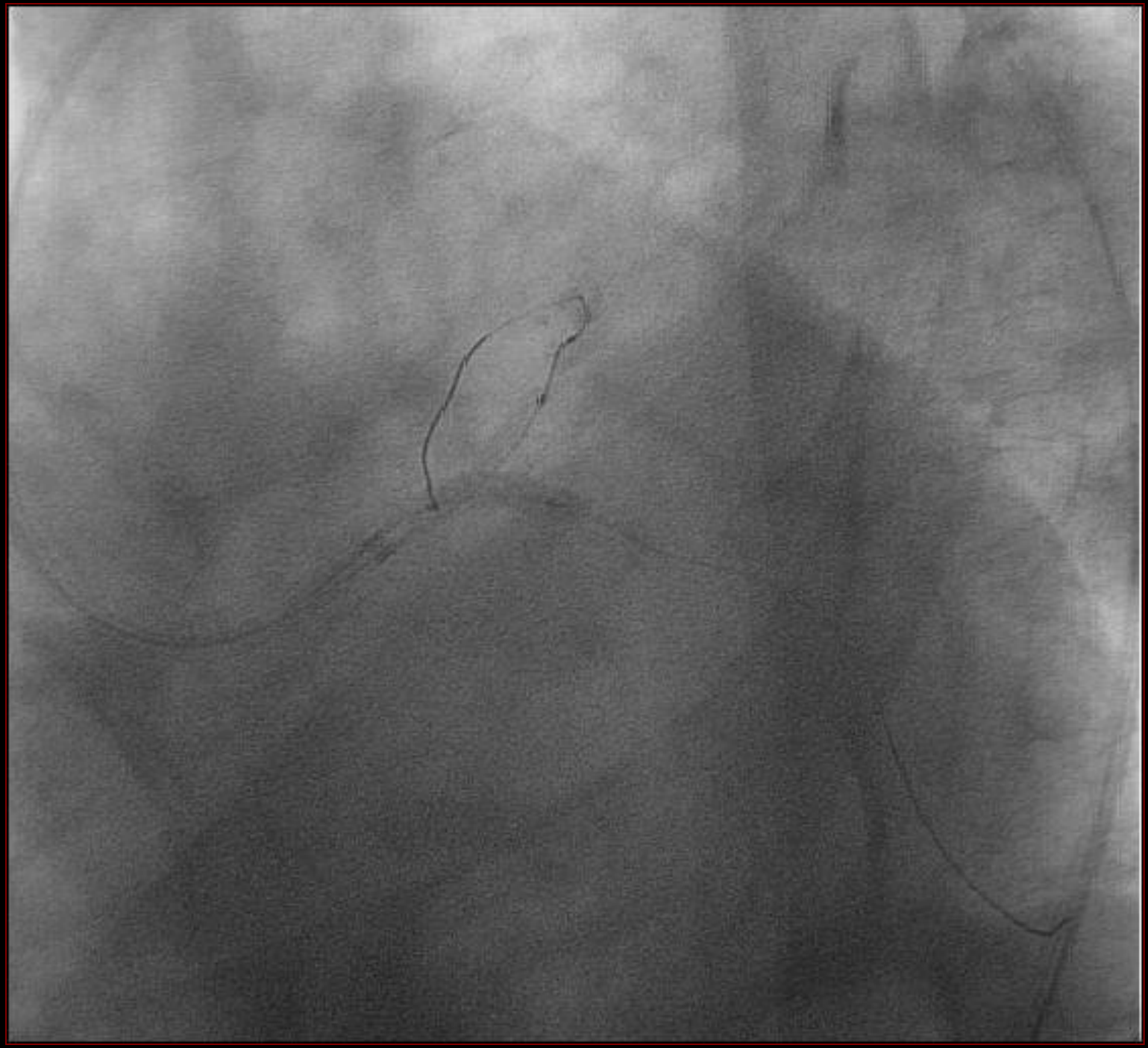

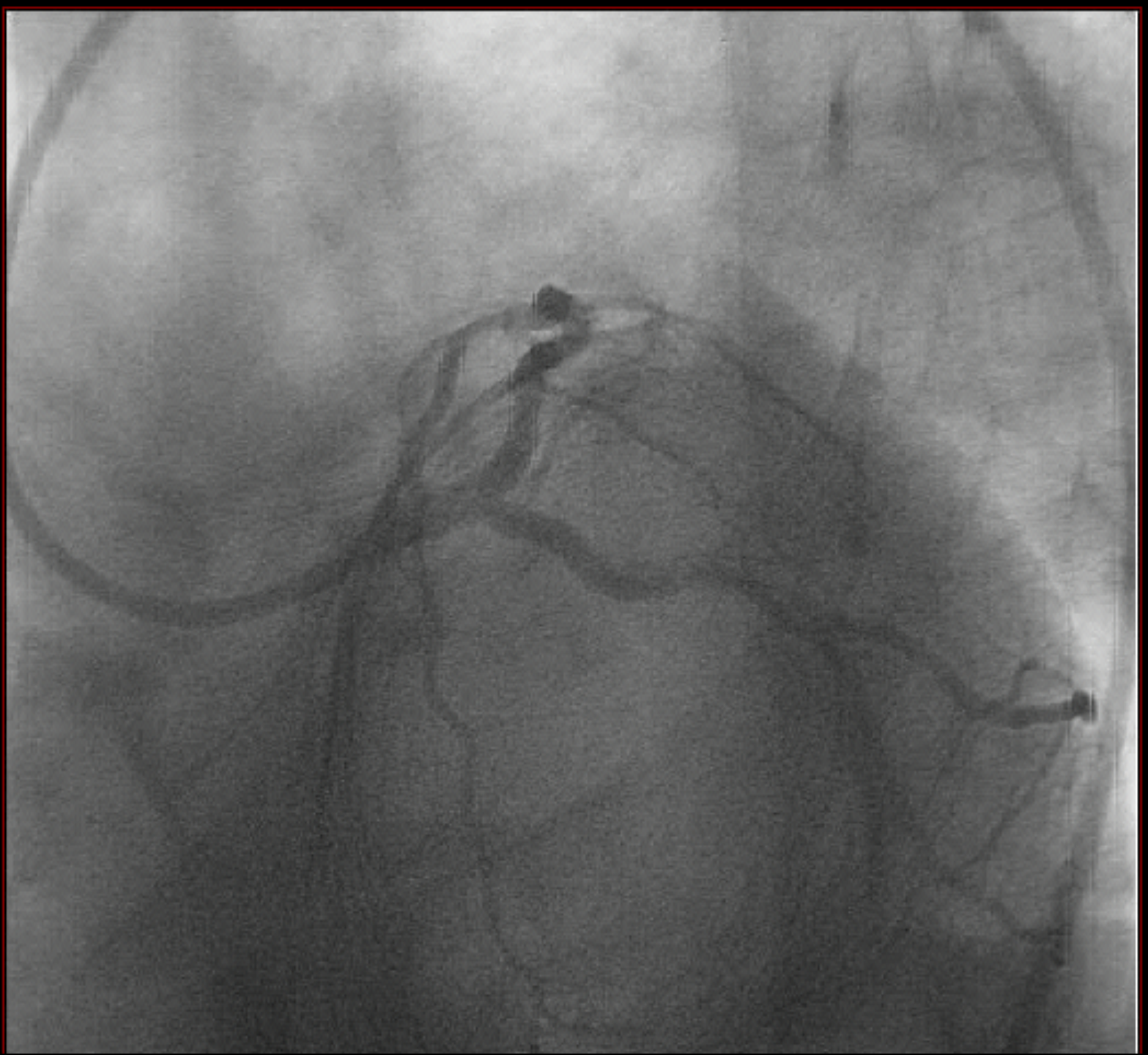

Step By Step Description (1)

1. Advance two wires to main vessel (MV) and side branch (SB)
2. Predilation of both MV and SB (consider some type of lesion preparation)
3. Advance stent to SB distal to bifurcation
4. Advance stent to MV (locate in its final position)
5. Place SB stent only 1 mm inside MV
6. Deploy SB stent

7. Withdraw balloon of SB stent to guiding catheter
8. Angiogram to rule out distal dissection on side branch
9. Withdraw guide wire of SB to guiding catheter
10. Deploy MV stent and advance balloon distal to stent
11. Recross wire to side branch (often a new wire –Pilot 50- or Grand Slam needed)
12. Insert balloon in side branch (often new needed) and inflate at high pressure
13. Withdraw MV balloon and do final kissing at intermediate pressure
14. Withdraw both balloons and final angiogram



Modified Crush Technique

Or

you have a disaster
after SB predilatation

Step by Step Description (1)

1. First 3 steps same than original crush
2. **Advance balloon to MV**
3. Place SB stent 1-2 mm inside MV
4. Deploy SB stent
5. Withdraw balloon of SB stent to guiding catheter
6. Angiogram to rule out distal dissection in SB

Step by Step Description (2)

6. Withdraw guide wire from SB to guiding catheter
7. **Inflate balloon in MV to crush SB stent**
8. Withdraw balloon from MV **and insert stent**
9. Deploy MV stent and advance balloon distally
10. Final steps the same than in original crush

TIPS & TRICKS

1. Do a good **predilation** for good visualization and adequate stent expansion
2. Consider some type of **lesion preparation** (Cutting, Rotational atherectomy)
3. Maintain both guidewires separated and well identified
4. **Minicrush is the way to go** (easier and more efficient)
5. Recrossing the Cx stent often requires hidrophylic wire and a big loop (or Grand Slam wire)
6. If used balloon does not cross (new 1.5/6 mm balloon)
7. If still does not cross, on the wire balloon (ACE)
8. High pressure inflation in Cx and moderate pressure final kissing

Left main PCI

n = 101 .

Follow up =25,3 months (14.1-44.8 months)

Age	69±11 yrs
Male gender	77
Diabetes	31
Previous MI	25

RISK PROFILE

CD occluded or severily stenosed	58%
Age > 75 yrs	30%
MVD	90%
EF<40%	27%

Procedural Data

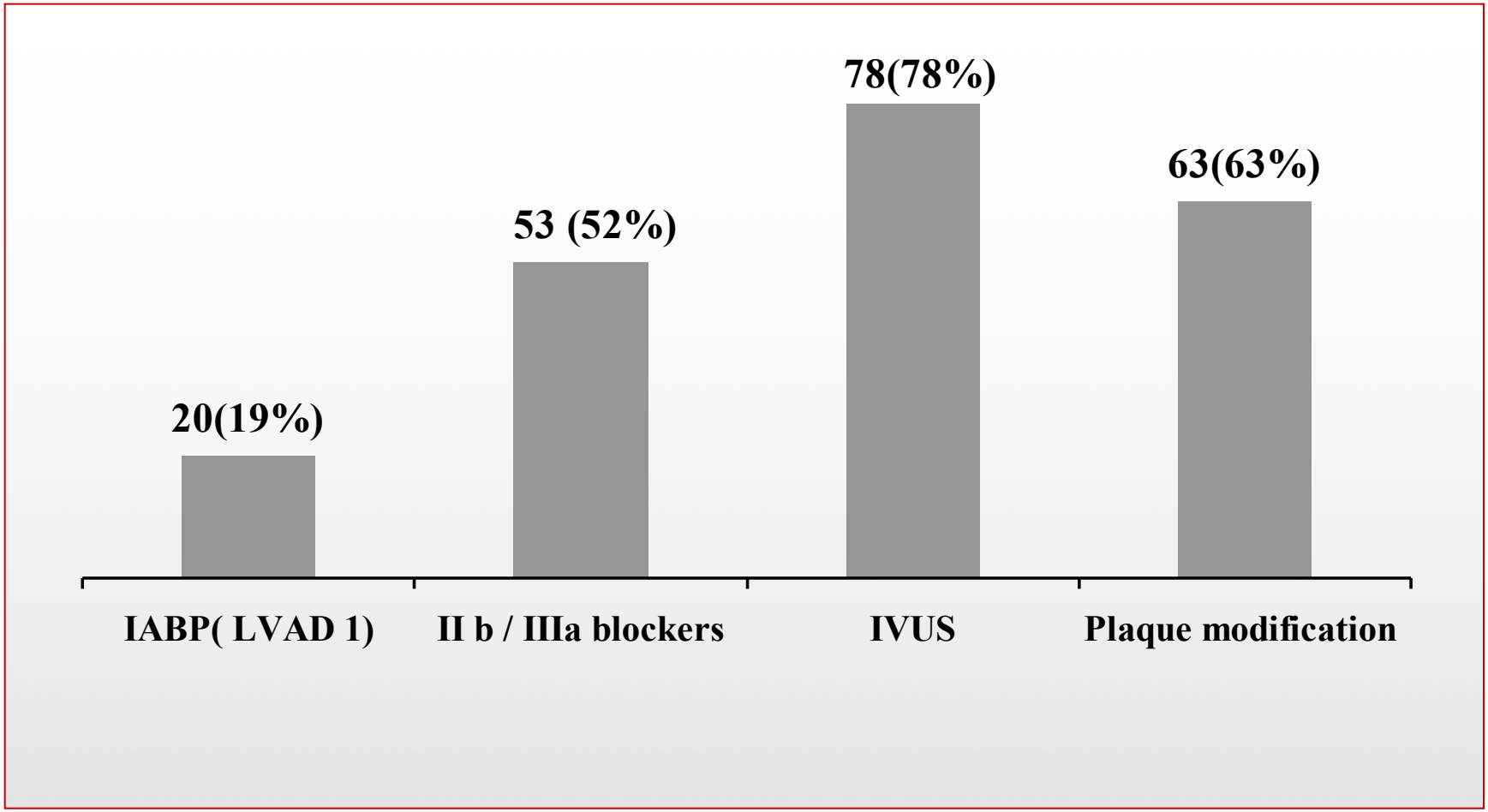

Angiographic Parameters

	Pre	Post
MLD	1.5 ± 0.5mm	3.3 ± 0.5mm
% stenosis	57.9 ± 10.2	10 ± 6.4 mm
Distal location	66%	
Final kissing balloon	100%	
Cutting balloon	50%	
Rotacional atherectomy	7%	
Direct stenting	4%	

Stent technique

One stent	50 (**49.5%**)
2 stents	51 (**50.5%**)
Final kissing	101 (**100%**)

IN-HOSPITAL RESULTS

Procedural Success	100 %
Clinical succes	95%
Cardiac death	1.7%
NQMI	3%
Transient CVA	0.6%
TVR	0

Longterm results

	12 months	25 months
Mortality	6%	6%
MI	3%	3%
TVR	9%	10%
Total MACE	18%	20%

TVR Narrative

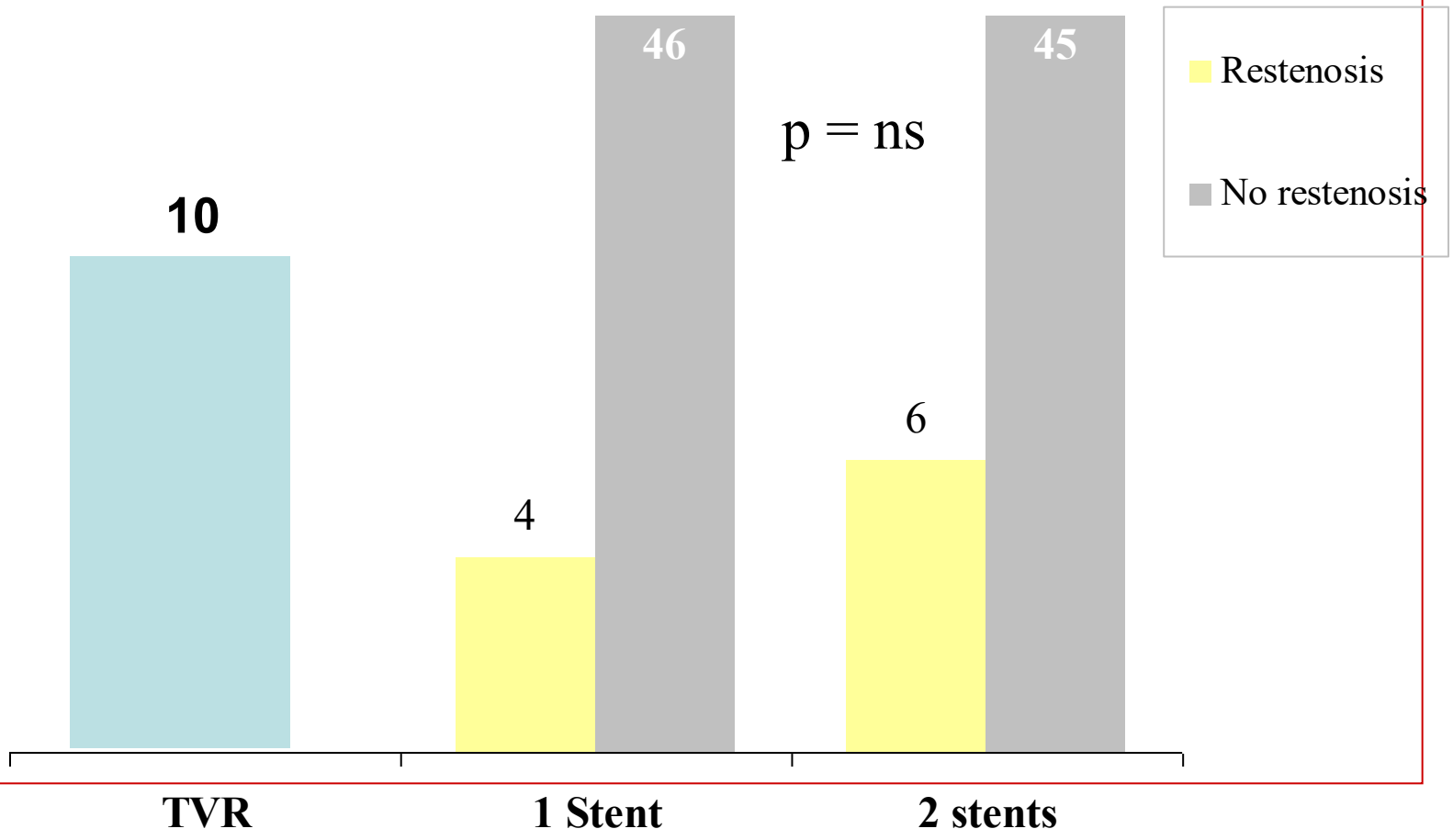

Mortality Narrative

1. 80 yr. CD occluded. **EF 30%** . Peri procedural MI. Cardiac rupture 5 days post procedure . **One stent**
2. 71 years. CD occluded. **EF 15%.** 19 days Admitted for CHF. Two days later cardiac arrest post VF. Unsuccessful PCR. **One Stent**
3. 75 years **EF 35%.** Severe aortic stenosis. Severe hypotension. EM disociation. **Two stents**
4. 78 years. 7 days later. Occlusion LAD (non treated lesion) Anterion MI. **Shock**. **One Stent**
5. 83 years old . **EF 20%.** Sudden death 5 mo. Post procedure. **Two Stents**
6. 70 years old. **EF 18%.** CHF and death 1 month post procedure. **Two Stents**

Predictors of Mortality

	1 mo	12 mo
EF	0.91 (95% CI: 0.86-0.99)	0.76 (95% CI: 0.59-0.98)

CONCLUSIONS

LM treatment in the era of DES

- Safe and effective
- Sustained clinical result at long term follow up.
- No difference in outcome among different tailored approaches
  - 1 stent only + final kissing
  - Minicrush

Thank you