DCA revival in bifurcation treatment

Yoshihisa Kinoshita, MD

Toyohashi Heart Center

Disclosure

I do not have any potential conflict of interest.

DCA Mechanism

Pre-Drug-Eluting Stent Debulking of Bifucated Coronary Lesions <PERFECT>

Tsuchikane E, et al. J Am Coll Cardiol 2007;50:1941–5.

Ostial or bifurcated lesion
Distal LMT, ostium of LAD or LCx, or major bifurcation
Vessel Diameter: > 2.5mm

DCA ; IVUS target residual percent PA < 60%

Single or multiple SES Stenting ±KB or SB-dilation → **Complex stenting is only 2%.**

N = 99 patients
Japanese 17 sites
Non-randomized
Prospective Registry

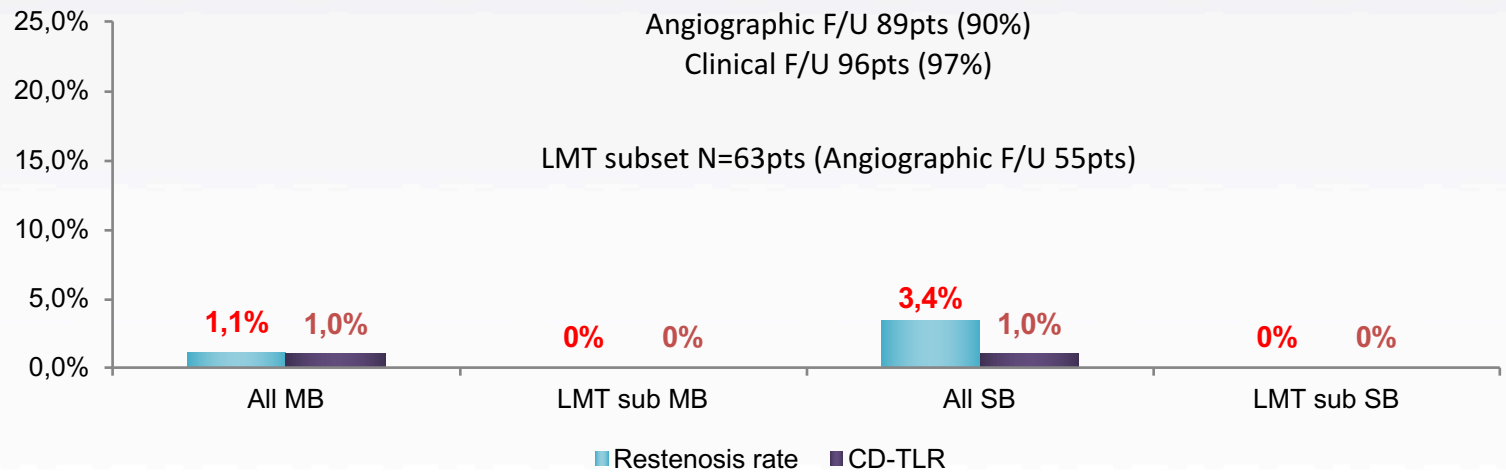

Unprotected Left Main Coronary Artery Bifurcation Stenosis

Impact of Plaque Debulking Prior to Single Sirolimus-Eluting Stent Implantation

Tanaka N, et. al. J INVASIVE CARDIOL 2008;20:505–510.

***de novo* unprotected LMCA lesions**
Single SES implanted
from the LMCA to the LAD across the LCx ostium

DCA arm
(n= 41 patients)

N = 101 Patients
Single center
Retrospective , observational study
(Non-randomized)

Non-DCA arm
(n=60 patients)

(Number of Pts)	DCA + SES (41 pts)	SES (60 pts)	P-value
Freedom from MACE	97.4 ± 2.6%	88.6 ± 4.4%	0.129
%DS of LCx			
- baseline	36.8 ± 21.5%	26.9 ± 19.2%	0.029
- after PCI	19.2 ± 13.1%	28.3 ± 22.7%	0.034
- 9mo F/U	20.8 ± 12.3%	31.9 ± 21.4%	0.007
Restenosis rate			
- Stented site	2.7%	6.1%	0.472
- LCx ostium	0%	10.2%	0.048

FLEXICUT ⇒ ATHEROCUT

	ATHEROCUT®	FLEXICUT®
≪Material≫		
(Cutter) 	Diamond-like coating (Vickers Hardness：900)	
≪Specs≫		
Max OD 	Φ1.95mm (0.077inch)	
Window length	6mm / 9mm	
Target vessel diameter	3.0-4.4 mm (3 types)	
Nose cone 	Tapered nose-cone with tip	
Compartible Guiding cathter	More than 7Fr 8Fr is better.	
Rotational speed of MDU 	6,000rpm	

Case: 70's female; LMT DCA

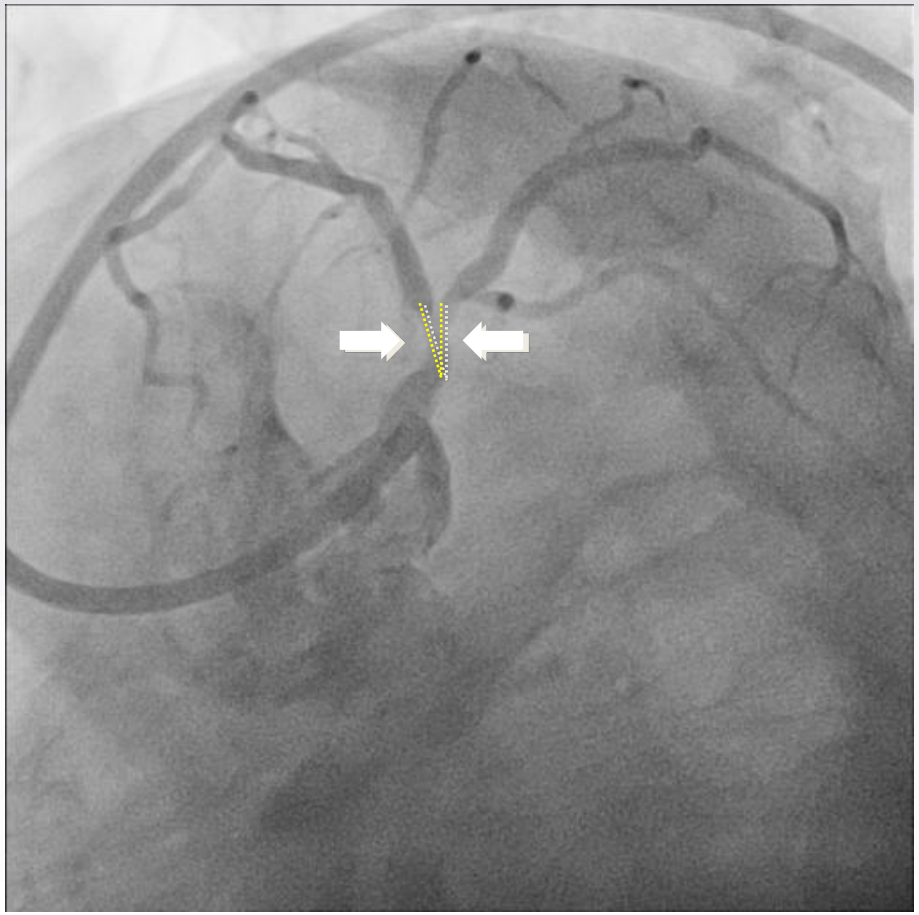

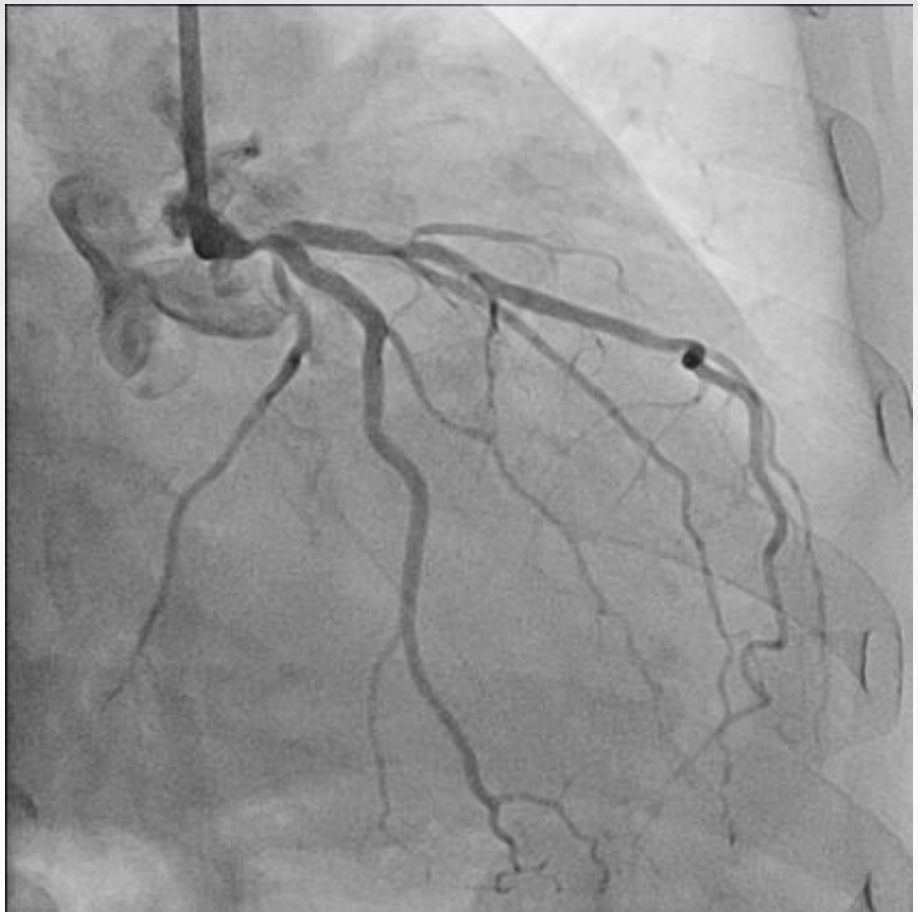

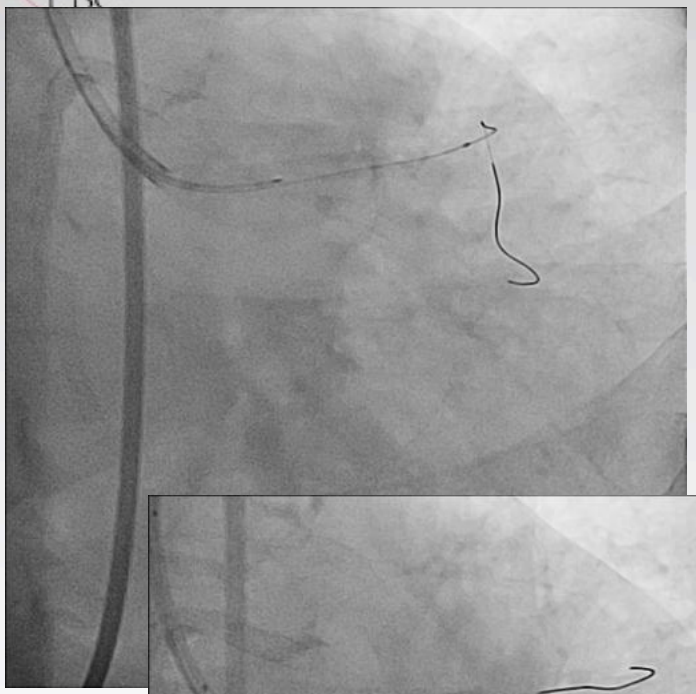

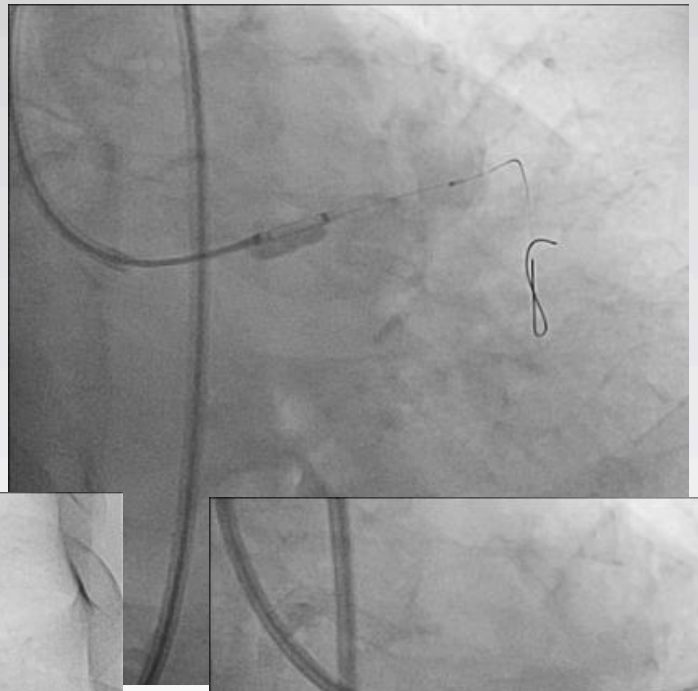

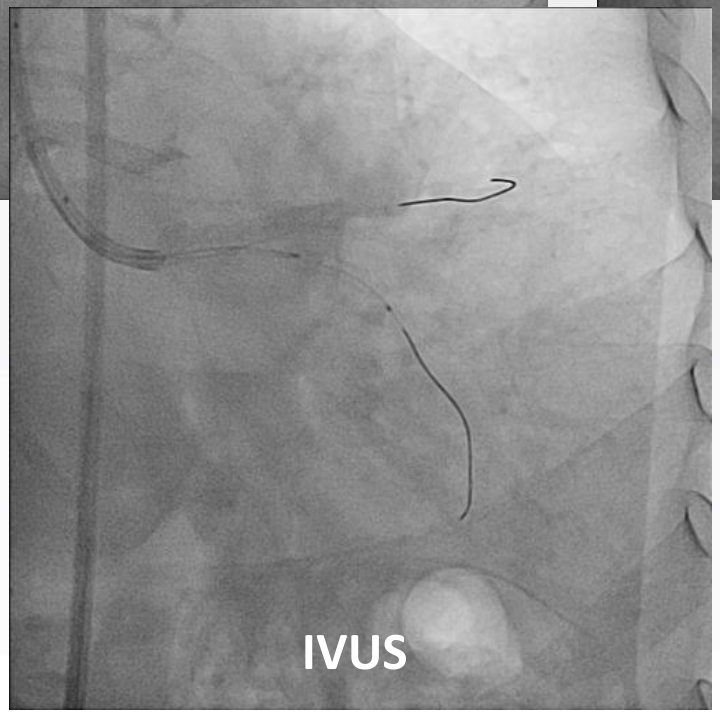
IVUS

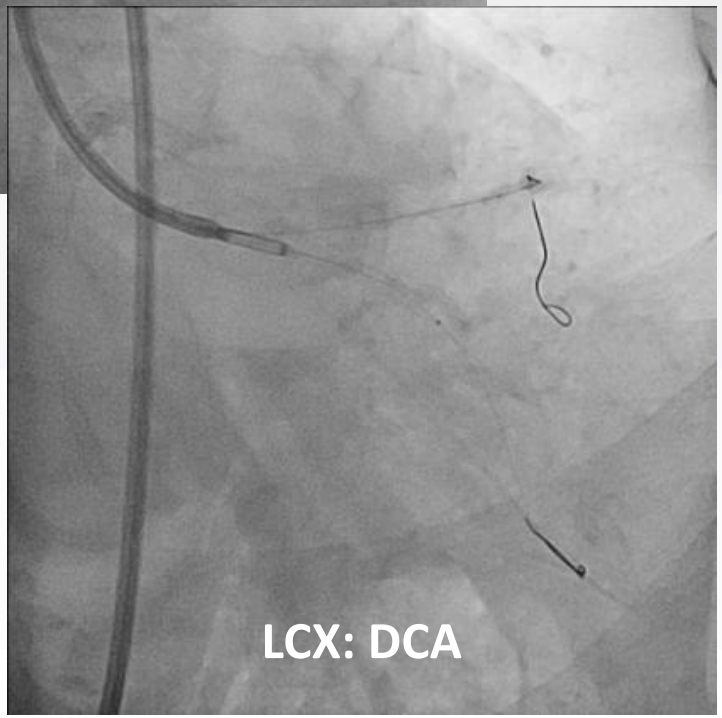
LCX: DCA

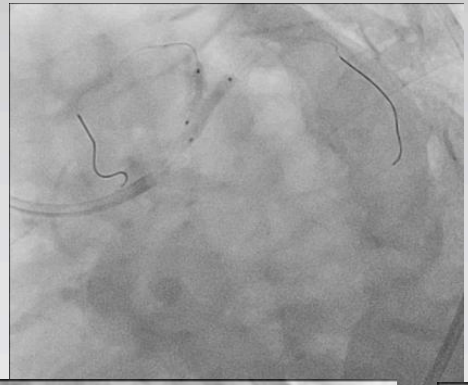

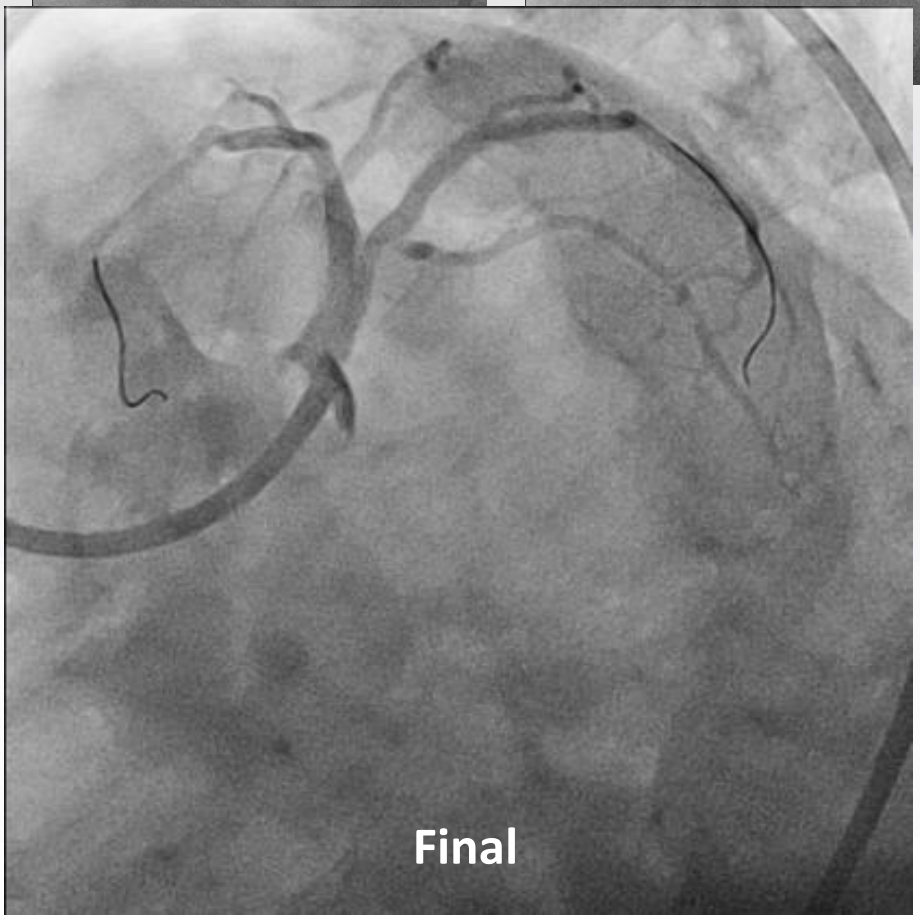
Final

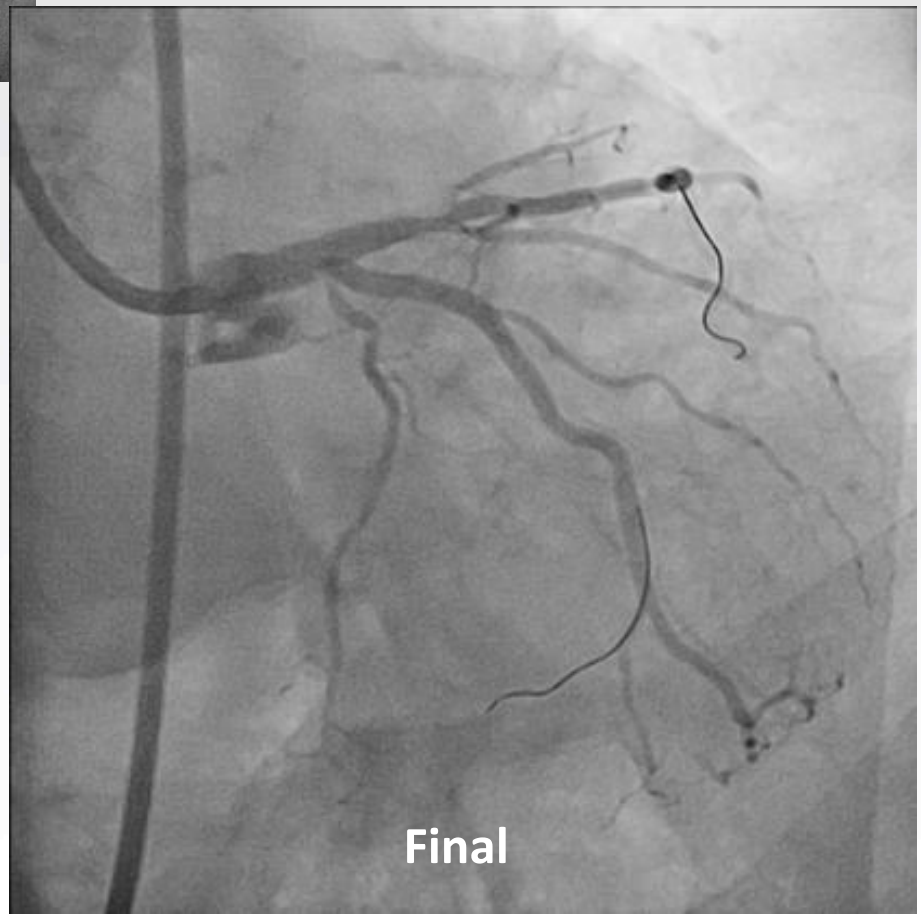
Final

Case: 60's male; LCX DCA

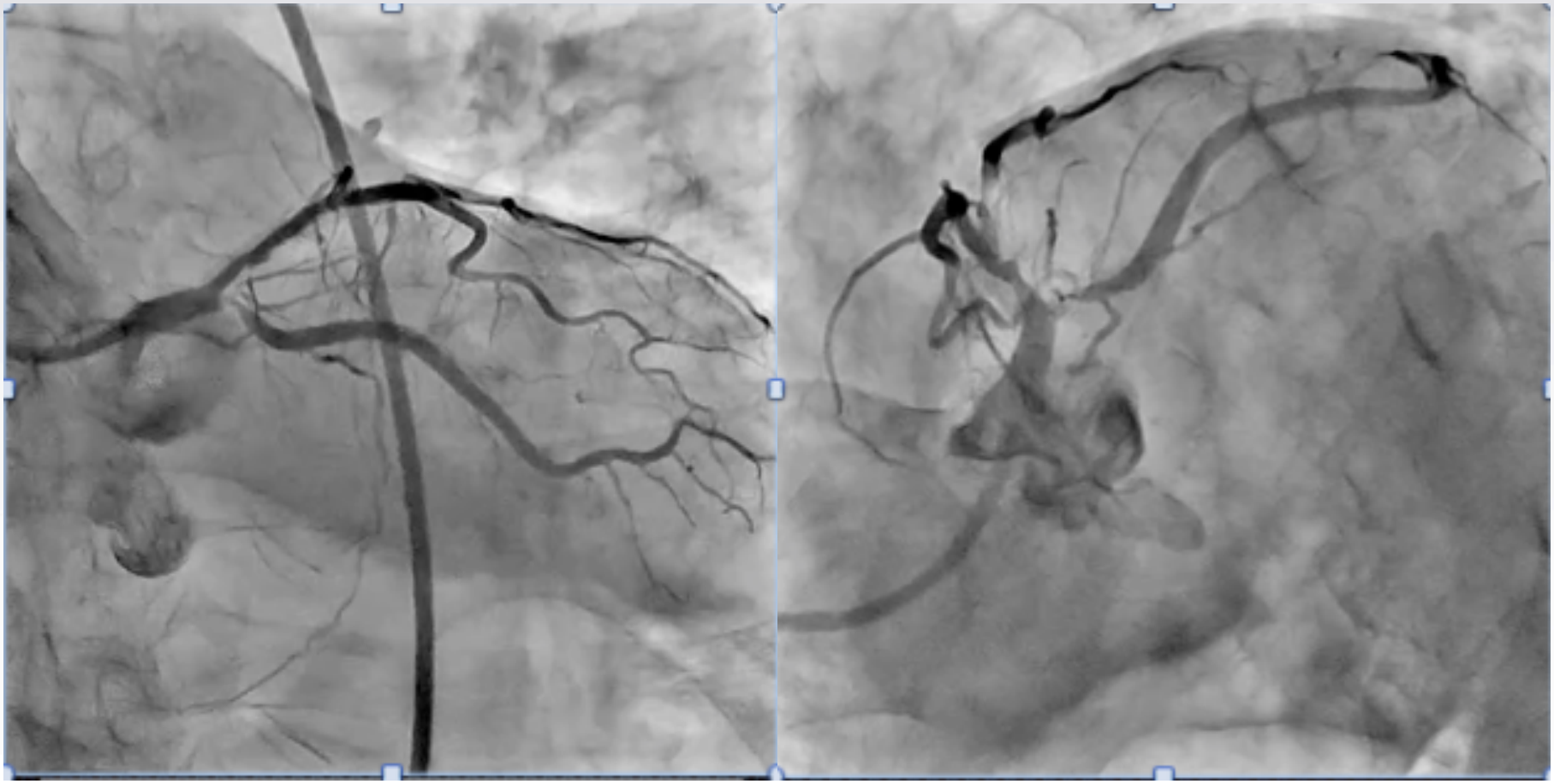

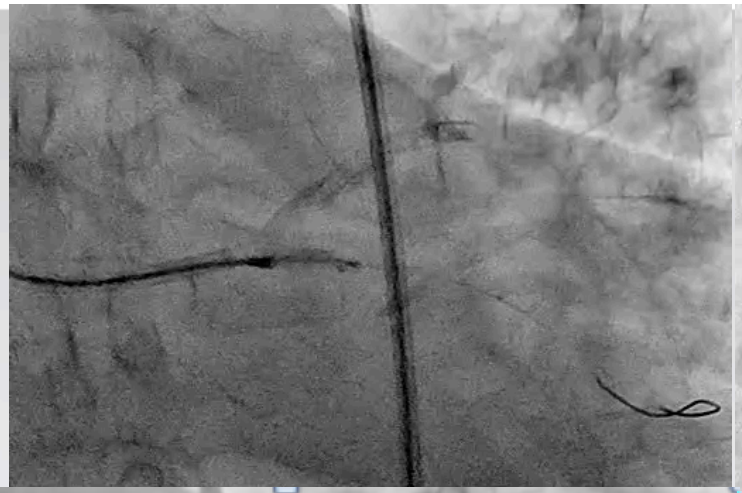

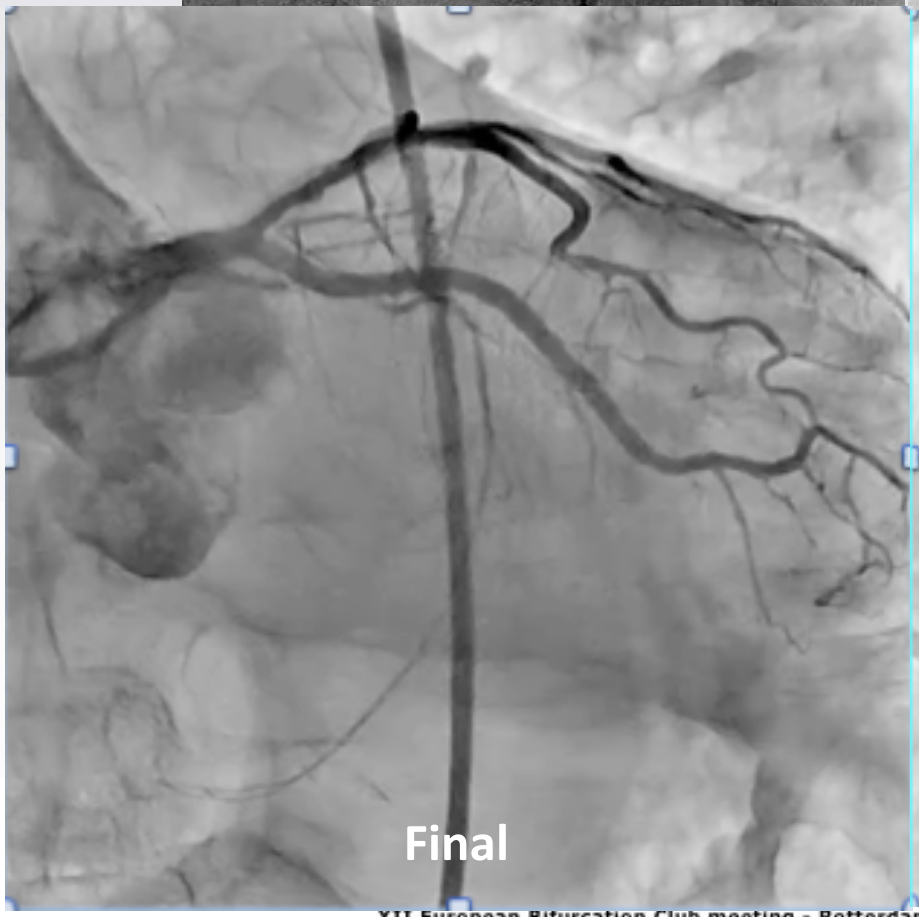
Final

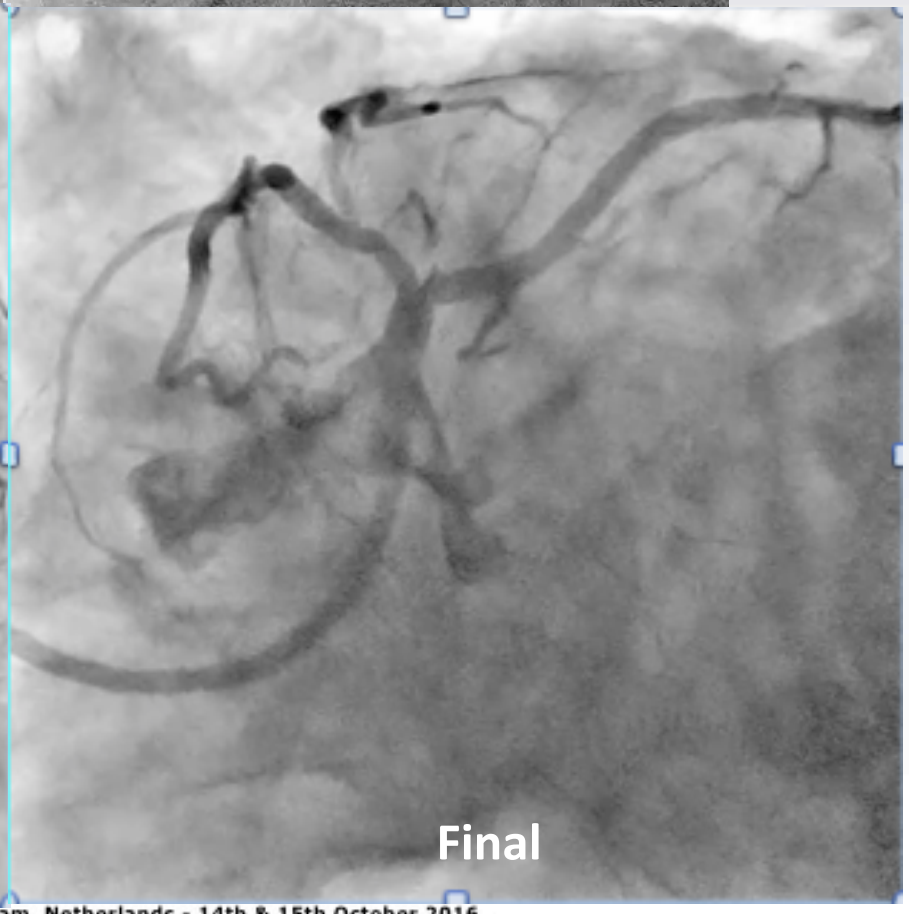
Final

New DCA ATHEROCUT®
Early Clinical Experience
From Mar 2015 – Jul 2016

Patients Characteristics

	(Mar.15'-Jul.16')
Number	39
Male	32 (82%)
Age (y.o)	67.5 ±11.2
Prior MI	8 (21%)
Prior CABG	0 (0%)
UA	0 (0%)
HT	20 (51%)
DM	11 (28%)
HL	26 (67%)
H/O smoking	13 (33%)

Lesion Location
Bifurcation type
(N=39)

LMT Bifurcation	LAD Ostial	LCx Ostial	LAD/Diagonal	LCx/OM
12 (31%)	**19 (49%)**	3 (7%)	5 (13%)	0 (0%)

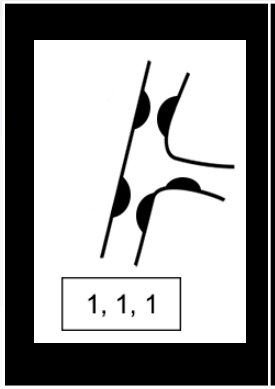	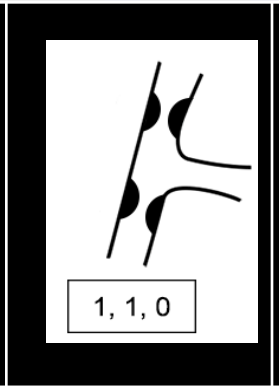		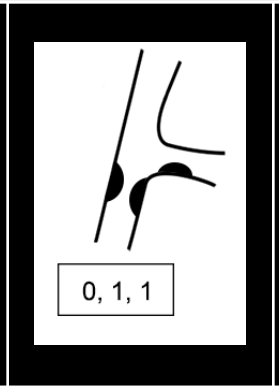	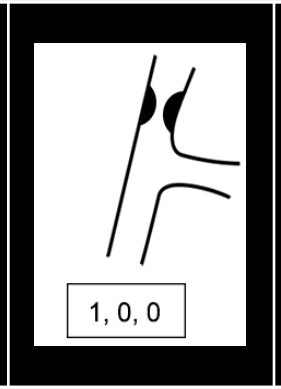	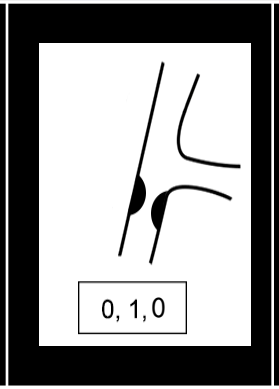	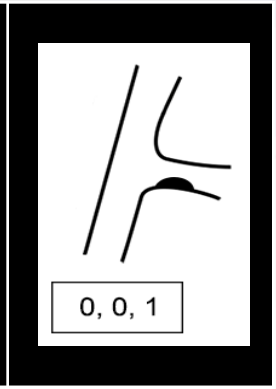
1, 1, 1	1, 1, 0	1, 0, 1	0, 1, 1	1, 0, 0	0, 1,0	0, 0, 1
4 (10%)	8 (21%)	1 (3%)	0 (0%)	2 (5%)	**20 (51%)**	4 (10%)

Almost half of lesions were LAD ostium (0,1,0).

DCA Procedural Results

(n=39)

Complications during DCA

1) spasm	0%
2) side branch occlusion	0%
3) no flow	0%
4) perforation	0%

DCA Procedural Results

(n=39)

1. ATHEROCUT® size L/M: 32/8※

2. Max. cutting pressure: 5.3 ± 2.5 atm

3. No of cut: 16.0 ± 8.2 cut

4. Vessels treated by DCA

1) Main branch alone	37 (95%)
2) Both main and side branch	2 (5%)

5. Post DCA %PA: 50.3 ± 9.5 %

※ 1 Left Main bifurcation (1,1,1) case :
L size for LM-LAD / M size for LM-LCx

Stenting Procedural Results

(n=39)

None (DCA alone)	**15**	**38%**
Stenting		
Crossover		
1 STENT + KBT	**8**	**21 %**
1 STENT + Non KBT	**5**	**13 %**
1 STENT + SB-POBA	**1**	**3 %**
Non crossover	**10**	**26 %**
Complex Stenting	**0**	**0 %**

KBT: kissing balloon techique; SB: side branch
Complex stenting : Crush T- Culotte stenting

Procedural Results

(n=39)

1) Device success : 100%
2) Procedure success : 100%
3) Amount of Contrast Medium :205.9±66.8cc
4) Procedure Time :110.2±24.8min
5) Fluoroscopy Time : 40.3±11.6min

In-Hospital Outcomes

(n=39)

1) Death	0%
2) Em-CABG/TLR	0%
3) QMI	0%
4) Non-QMI	0%
5) Complication at access site	0%

Angiographic Follow-up Results
N=11

- DCA alone : 4

  Crossover Stenting + KBT : 3

  Crossover Stenting + SB-POBA : 1

  Non-crossover :3

- Fu duration: 196.3 ± 93.7 days

- Binary restenosis rate

  Main branch: 0%(0/11)

  Side branch: 0% (0/11)

Benefit of DCA in Bifurcation

- **Prevention of carina and plaque shift.**
- **Avoidance of complex stenting.**
- **Short duration of DAPT.**

Although we need precise understanding of relationship between CAG & IVUS finding.

Thank you for your attention!!