The difficult Side Branch wiring

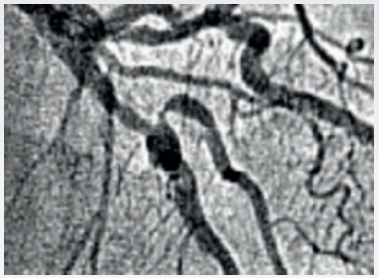
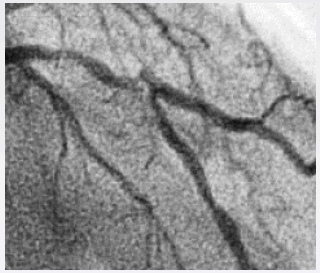

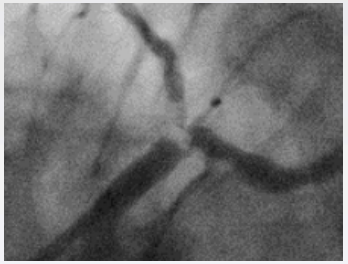
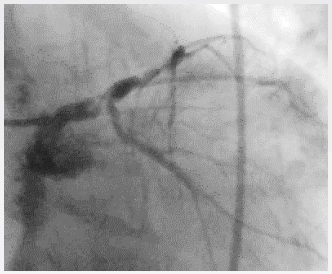

I. Sheiban

Director Interventional Cardiology

Pederzoli Hospital

Pescheria del Grada (Verona)/ Italy

e-mail: isheiban@gmail.com

Challenging Side Branch access :

- One of the most important stenps in BL interventions is Successful wiring of the side branch for treatment or protection

- Usually this is performed without difficulty. However; in some anatomical subsets and sometime after stenting MV , SB wiring is challenging

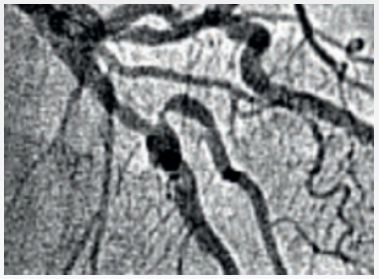
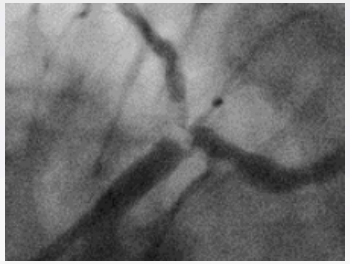
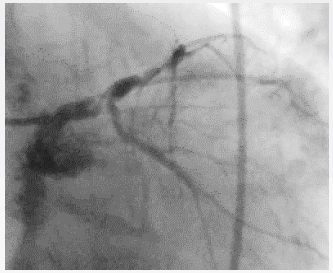
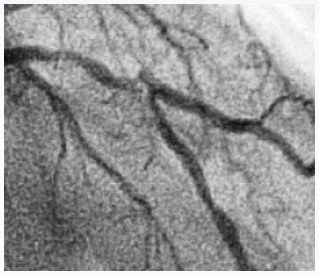


Challenging Side Branch access :

Start with simple tips and triks

- **Selecting the optimal view to better see th origin of SB**
- **Selecting and Shaping approprtiately the guide wire accodrdingly to side branch angolation, morphology and anatomy**

Common types of guidewire tip shape for BL

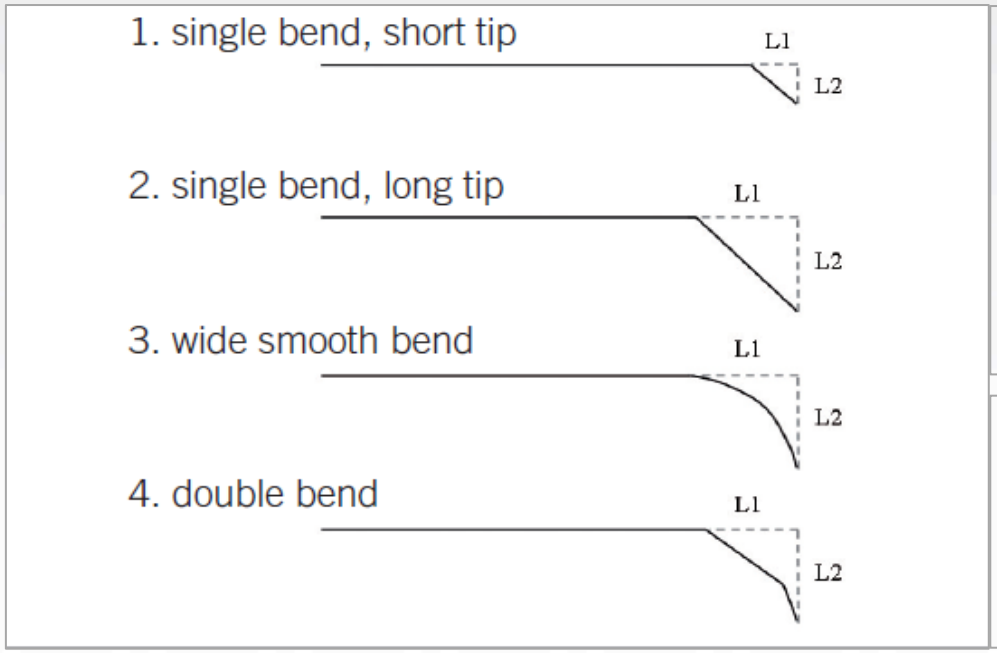

- **There is no a standard guide wire shaping that can be recommended for each challenging SB .**
- **Personal opertator *experience* and *creativity* sometime can play and important role …..**

- **Creativity is limited since shaping the guide wire tip with more curves is often translated in less control on maneuverability of guide wire**

F Burzotta et al ; EuroIntervention Supplement (2010) Vol. 6 (Supplement J) J72-J80

Challenging Side Branch access :

Start with simple tips and triks

POT : After stent deploment in MV , proximal Optimization Technique (POT) facilitates correct crossing the stent to SB

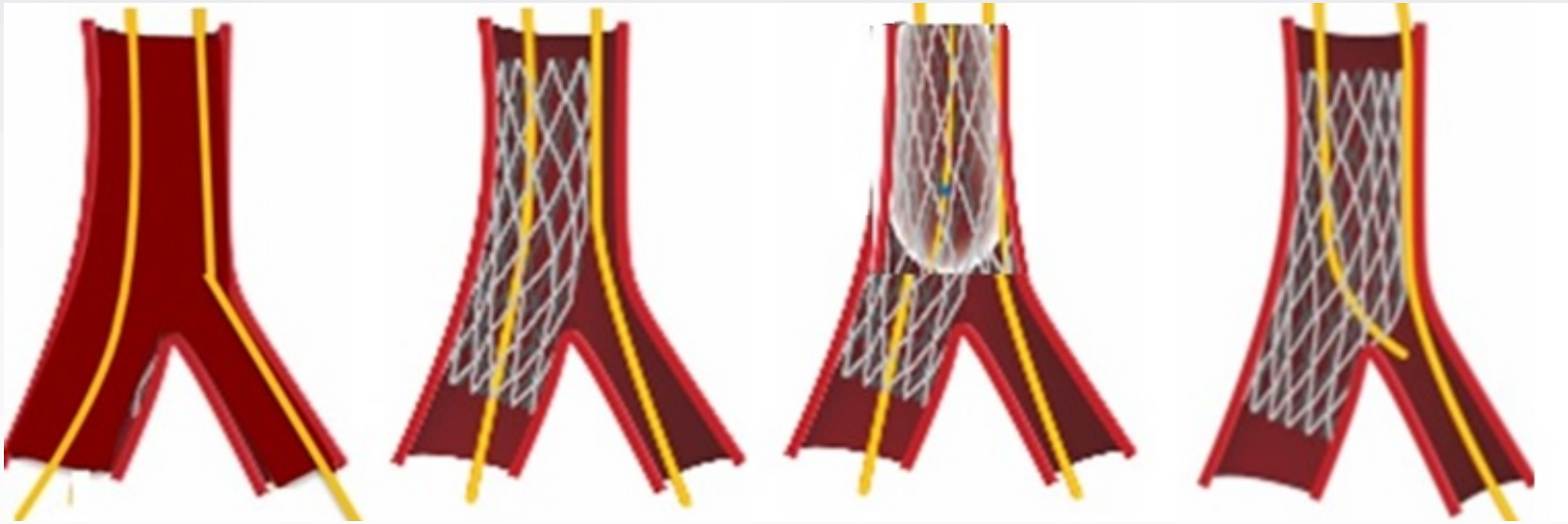

Stenting MV **POT** **POT facilitate distal crossing to SB**

Challenging Side Branch access :

Beside simple tips and tricks :

Different alternatives techniques have been described based on case reports or small studies including personal operators experiences :

- **Balloon Backstop**
- **Reverse Wiring Technique**
- **Double Lumen Catheter**
- **Venture Catheter**
- **Steer-it Deflecting Tip Guidewire**

Challenging Side Branch access :

- **Balloon Backstop Technique**

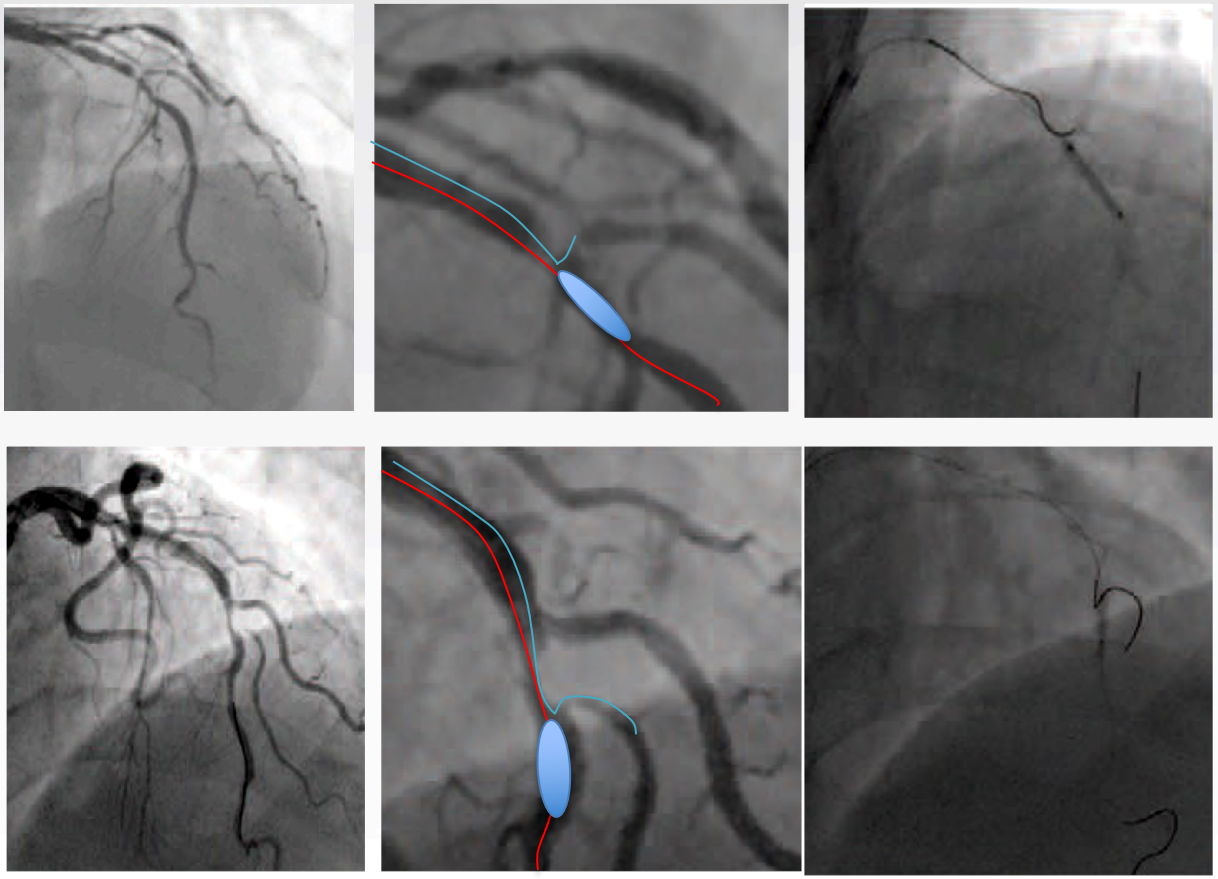

Limitations :

- **Induce ischemia then cann't be prolonged**
- **In diseased SB can induce damage and dissection on SB**

Challenging Side Branch access :

Reverse Wiring Technique (Reverse Hook Technique)

- Guidewire is smoothly curved to shape a large distal bend (J tip shape)
- In extremely angeld SB "a hair-pin bend" shaping at about 5 cm from the wire tip is more appropriate to engage SB

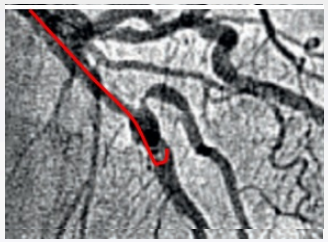

- Shaped Wire is advanced in distal MV

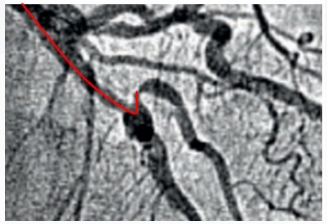

- Wire is pulled back toward the bifurcation. Due to the hook-like bend the distal tip of the guidewire can engage the side branch.

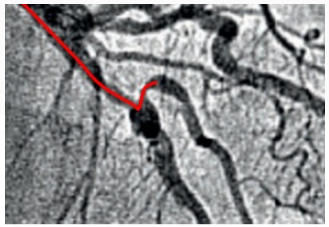

- When SB is engaged the wire is advanced in side branch by gentile turning counter-clockwise

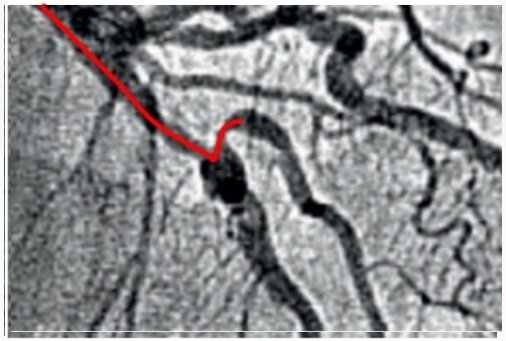

Challenging Side Branch access :

Dual Lumen Catheter Technique

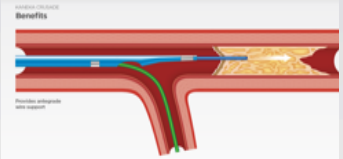

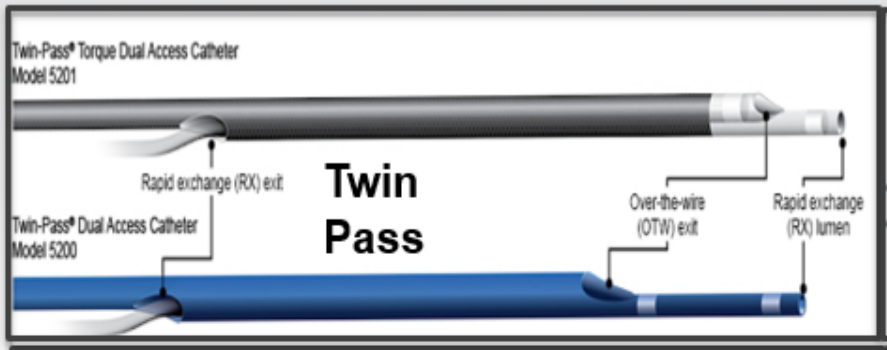

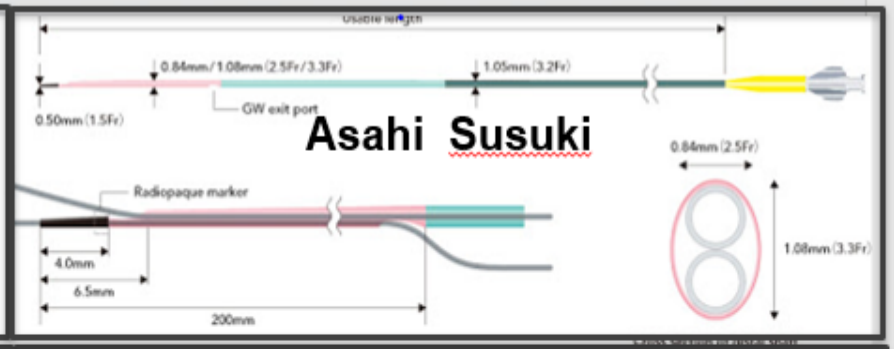

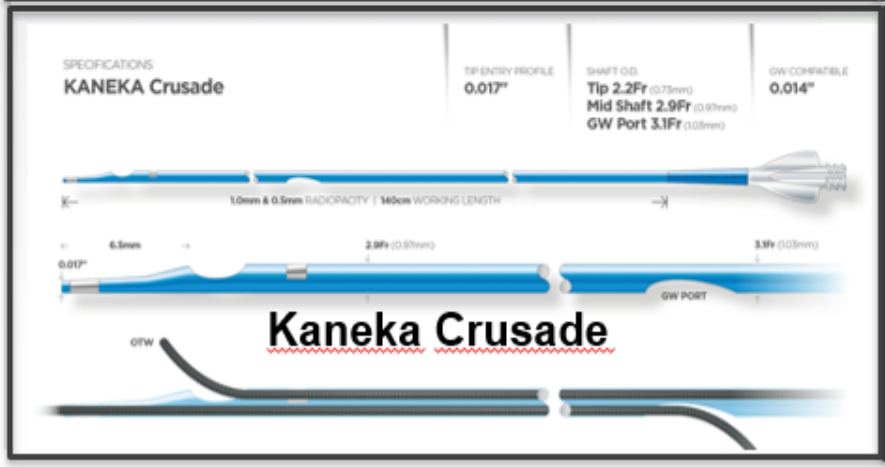

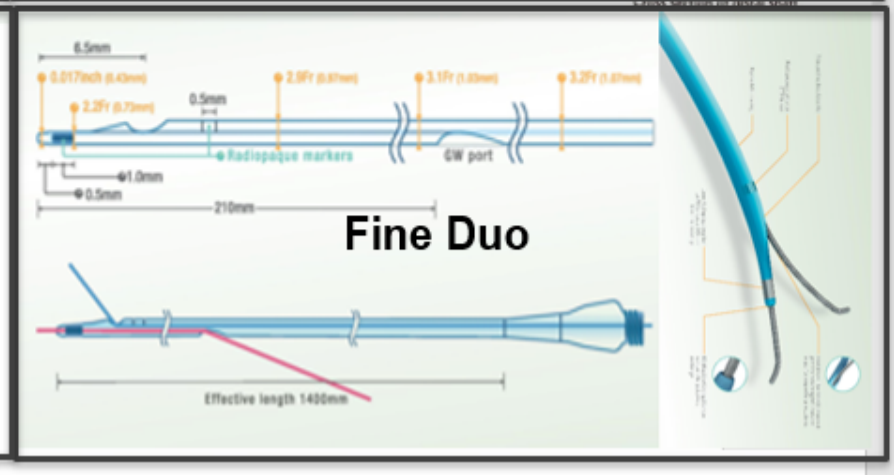

Challenging Side Branch access :

VENTURE CATHETER

- **0.014-inch wire compatible catheter with a deflectable tip .**
- **The tip can be oriented and deflected up to 90º and well controlled by a knob on the proximal handle of the catheter**
- **Catheter tip directed to the SB or directly into a side branch and advance the wire**

Limitation :

- **Require good specific experience**
- **Tip deflection is unpredictable in terms of direction**
- **Cannot be used in relatively small vessels *(catheter and deflected tip may be too large for the vessel lumen)***
- **Risk of vessel injury with the deflection of the tip.**



Tip deflection is activated and controlled by turniong Knob on proximal handle

Tip can be deflected from straight to 90 degrees

Tip deflected in direction of SB and wire advaced

Challenging Side Branch access :

STEER-IT DEFLECTING TIP GUIDEWIRE

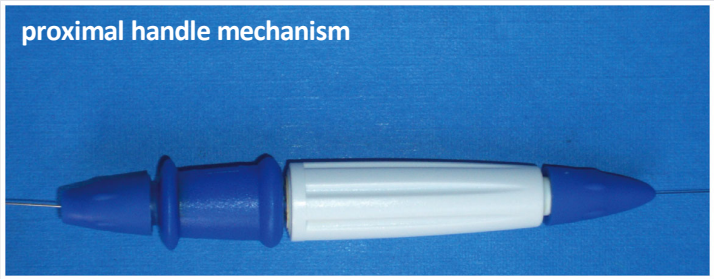



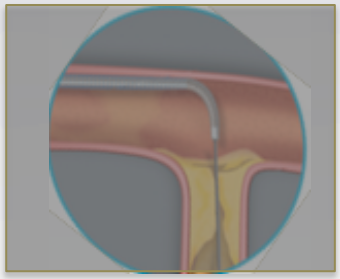

- .014-inch guidewire with a flexible radiopaque platinum alloy coil on the distal tip.
- Distal tip is deflectable bidirectionally by proximal handle mechanism of the guidewire.
- Similar mechanism to the Venture catheter,
- Can be guided into a severely angulated side branch

Limitations:

- Might be more difficult to advance the wire as compared to convetional wires
- Deflectable tip may predispose to vessel injury *(wire is deflected or advanced in the wrong direction or into the vessel wall).*

Challenging Side Branch access :

Predilatation of main vessel in very tight lesions proximal to bifurcation

(Difficult crossing with bended wire / Difficult manovaurabilty of bended wire to enter SB)

- **Prdilataion with small balloon at low pressure to create more space for bended wire to advance**
- **Following MV dilatation appropriately shaped wire can be tracked to the bifurcation and access SB**
- **In heavily calcified lesions, Rotablation with small barr 1.25/1,5 mm in MV can be performed instead of balloon predilatation**

"Last Resort "..

Risk of:
plaque shifting / plaque dissection and SB occlusion !!!

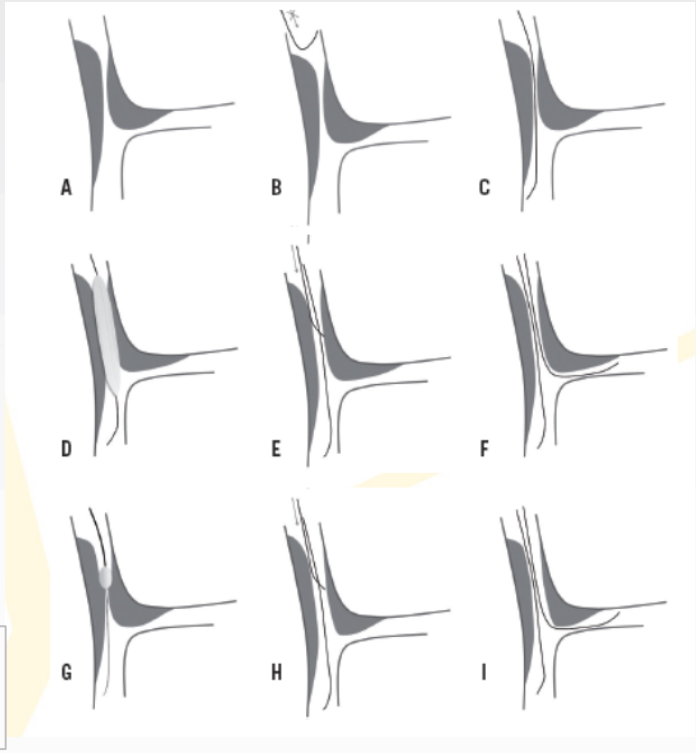

Burzotta et al EuroIntervention 2011

EBC

Take Home Message

- **SB wiring is essential in bifurcation intervention for protection and for an optimal interventional approach (simple or copmplex)**
- **Side branch access can be technically challenging in different anatomical subsets** ***(extreme angulations, extreme tortuosity , severe side branch ostial disease)***
- **Given the variability of anatomical challenges there is no a standard technique to access SB : good experience, appropriate wire selection and shaping play an important role**
- **The techniques described previously may be useful if used in the appropriate anatomical setting and with the required experience**